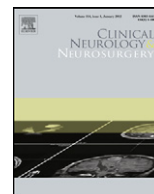




Contents lists available at [SciVerse ScienceDirect](http://www.elsevier.com/locate/clineneuro)

Clinical Neurology and Neurosurgery

journal homepage: www.elsevier.com/locate/clineneuro



A clinical analysis on microvascular decompression surgery in a series of 3000 cases

Jun Zhong, Shi-Ting Li*, Jin Zhu, Hong-Xin Guan, Qiu-Meng Zhou, Wei Jiao, Ting-Ting Ying, Xiao-Sheng Yang, Wen-Chuang Zhan, Xu-Ming Hua

Department of Neurosurgery, XinHua Hospital, Shanghai JiaoTong University School of Medicine, The Cranial Nerve Disease Center of Shanghai, Shanghai 200092, China

ARTICLE INFO

Article history:

Received 28 June 2010
Received in revised form
17 November 2011
Accepted 15 January 2012
Available online xxx

Keywords:

Microvascular decompression
Conflict site
Trigeminal neuralgia
Hemifacial spasm
Surgery
Approach

ABSTRACT

Objective: Despite the microvascular decompression (MVD) has become a definitive treatment for trigeminal neuralgia (TN) and hemifacial spasm (HFS), not all of the patients have been cured completely so far and this sort of operation is still with risk because of the critical operative area. In order to refine this surgery, we investigated thousands MVDs.

Methods: Among 3000 consecutive cases of MVDs have been performed in our department, 2601 were those with typical TN or HFS, who were then enrolled in this investigation. They were retrospectively analyzed with emphasis on the correlation between surgical findings and postoperative outcomes. The differences between TN and HFS cases were compared. The strategy of each surgical process of MVD was addressed.

Results: Postoperatively, the pain free or spasm cease occurred immediately in 88.3%. The symptoms improved at some degree in 7.2%. The symptoms unimproved at all in 4.5%. Most of those with poor outcome underwent a redo MVD in the following days. Eventually, their symptoms were then improved in 98.7% of the reoperative patients. The majority reason of the failed surgery was that the neurovascular conflict located beyond REZ or the offending veins were missed for TN, while the exact offending artery (arteriole) was missed for HFS as it located far more medially than expected.

Conclusion: A prompt recognition of the conflict site leads to a successful MVD. To facilitate the approach, the craniotomy should be lateral enough to the sigmoid sinus. The whole intracranial nerve root should be examined and veins or arterioles should not be ignored. For TN, all the vessels contacting the nerve should be detached. For HFS, the exposure should be medial enough to the pontomedullary sulcus.

© 2012 Elsevier B.V. All rights reserved.

1. Introduction

Since Dandy [1] first described the compression of blood vessels on the root entry/exit zone (REZ) of the nerve as the etiology of trigeminal neuralgia (TN) or hemifacial spasm (HFS), the theory of neuro-vascular conflict has been widely accepted today. Although, there are varied treatments for TN or HFS, e.g., trigeminal rhizotomy, thermocoagulation, balloon compression, medication of Carbamazepine or Botox injections, microvascular decompression (MVD) has become an effective treatment of TN and HFS nowadays [2], since Jannetta developed and popularized this surgical technique in the 1970s [3]. Nevertheless, this sort of the

surgical process is still with risk because of the critical operative area. Moreover, until now, not all of the patients with TN or HFS could be cured by MVD completely [4–7]. With accumulation of thousands MVD cases, we have realized that the postoperative outcomes hinged largely on the surgeon's manipulation. Theoretically, the symptom of pain or spasm should stop immediately following a successful operation. We assumed that the following two main factors accounted for a failed MVD: (1) the exact offending vessel was missed or not all the offending vessels were detached from the nerve; (2) the neurovascular conflict was inapproachable as a good anatomical angle was unavailable. Basically, a satisfactory MVD has been attributed to many details, for instance, the position, craniectomy, approach and closure as well as decompression. In order to obtain better surgical results and minimize complications, every single step should not be ignored while performing the operation. In this study, we retrospectively analyzed these MVDs completed in our center with emphasis on the correlation between surgical findings and postoperative outcomes. The strategy of each surgical process of MVD was detailed.

* Corresponding author at: The Department of Neurosurgery, XinHua Hospital, Shanghai JiaoTong University School of Medicine, The Cranial Nerve Disease Center of Shanghai, 1665 Kongjiang Rd., Shanghai 200092, China. Tel.: +86 21 25078003; fax: +86 21 65795173.

E-mail address: ZhongMDH@sju.edu.cn (S.-T. Li).

2. Materials and methods

From 2002 through 2011, 3000 consecutive MVDs have been performed in the department of Neurosurgery, XinHua Hospital, Shanghai JiaoTong University School of Medicine. These subjects consisted of 1282 cases of TN and 1332 cases of HFS plus 10 cases of coexistent TN and HFS as well as 42 cases of glossopharyngeal neuralgia, 5 cases of hemimasticatory spasm and 329 cases of those bilateral HFS or blepharospasm. Among them, 13 were those secondary TN or HFS caused by neoplasms. The age of the patient at the time of surgery ranged from 8 to 90 years old. The surgical data including intraoperative photos or video-recordings were registered for each case. Because of the limited number and debatable diagnosis or controversial indication, those glossopharyngeal neuralgia, secondary TN/HFS, hemimasticatory spasm, bilateral HFS or blepharospasm cases were rejected from this investigation. Four TN patients who were dead postoperatively were also excluded, which will be reported in our next paper in detail. As 9 of the 10 concurrent TN/HFS have been reported before [8], they were not addressed in this paper. Accordingly, 2601 MVDs were finally enrolled in this study.

2.1. Surgery

The patient was placed in a park bench position. The head was fixed in a Mayfield fixation frame. From 2010 on, the intraoperative abnormal muscle response (AMR) wave monitoring was adopted for HFS cases. A vertical linear incision was made behind the ear along and medial to the hairline. A craniectomy of 2.5 cm in diameter was performed in the posterior fossa. After the dura was sutured back, an operative microscope was brought into the field. Cerebrospinal fluid (CSF) was drained sufficiently to relax the cerebellum so that the operation could be performed without the use of retractors. The intracranial dissection started infrafloccularly for HFS cases, while laterocerebellarly for TN cases [8–10]. While the arachnoid membrane around the nerve was being opened, the vascular relationship was carefully studied to identify the vessels in contact with the nerve. Small pieces of shredded Teflon sponge were gently tucked in between the vessel and the nerve after the offending artery was detached from the nerve. After thoroughly irrigation to make sure there was no bleeding, the dura mater was closed with sutures in watertight pattern. A duragen was placed over the suture line. A cranioplasty of titanium wire mesh was completed. (Refer to Section 4 for the detailed differences between TN and HFS.)

2.2. Outcome assessments

Referring to the BNI score [11], the outcome was classified as excellent (symptom disappeared), good (occasional pain or spasm, not requiring medication), fair (some pain or spasm, controlled with medication) and poor (symptom remained without any improvement).

3. Results

Postoperatively, the pain free or spasm cease occurred as soon as the patient woke up from the anesthesia in 88.3% (excellent). The symptoms improved at some degree in 7.2% (good or fair). The symptoms unimproved at all in 4.5% (poor). Table 1 listed the immediate outcome in detail which was evaluated next day after the surgery. For those with poor outcome, a reoperation was performed within 2–5 days in 76 patients. Eventually, their symptoms were then disappeared or improved in 98.7% of the reoperative patients (Table 2). However, the residual 40 patients who had not undergone redo MVD did not change except for 2 HFS patients who gradually

Table 1

The early postoperative outcome.

Case	No.	Excellent (%)	Good (%)	Fair (%)	Poor (%)
TN	1274	1095 (86.0)	42 (3.3)	74 (5.8)	63 (4.9)
HFS	1327	1201 (90.5)	35 (2.6)	38 (2.9)	53 (4.0)
Total	2601	2296 (88.3)	77 (2.9)	112 (4.3)	116 (4.5)

TN, trigeminal neuralgia; HFS, hemifacial spasm.

Table 2

The outcome after the reoperation.

Case	No.	Excellent	Good	Fair	Poor
TN	46	38	4	3	1
HFS	30	27	2	1	0
Total	76	65	6	4	1

TN, trigeminal neuralgia; HFS, hemifacial spasm.

improved within 3 months. The majority reason of the first failed surgery was that the neurovascular conflict located beyond REZ for TN (Fig. 1) while the real offending artery was missed for HFS as it was far more medial than expected (Fig. 2). Sometimes, the offender was those very small vessels including veins [12]. The main complications included CSF leak (0.6%), the disturbance of hearing and balance (1%), facial palsy (1%) and hemifacial numbness (1%). The mortality was 4/3000 (0.13%). Out of the 2601 patients, 998 have been finally followed up for 3 years. Among them, 15 patients of TN recurred or deteriorated, while none of the HFS patients did.

3.1. Trigeminal cases

Among the 1274 cases of trigeminal neuralgia, the offending vessels were observed as artery only, artery combined with vein and vein only, respectively. Frequently, more than one offending vessel was found (74%), which included superior cerebellar artery (SCA, 41%), anterior inferior cerebellar artery (AICA, 29%), petrosal vein(s) (35%), posterior inferior cerebellar artery (9%) and vertebral artery (VA, 6%).

The conflict site was observed at the REZ (where the nerve enters the pons) in 54.8%, at the middle root in 36.2% and at lateral root (where the nerve comes from Meckel's cave) in 9.0%. The neurovascular conflicts were noticed as the following fashion with the relationship of the vessel(s) and the nerve: (1) contact in 22%, (2) impress in 26%, (3) adhesion in 40% and (4) penetration in 12%.

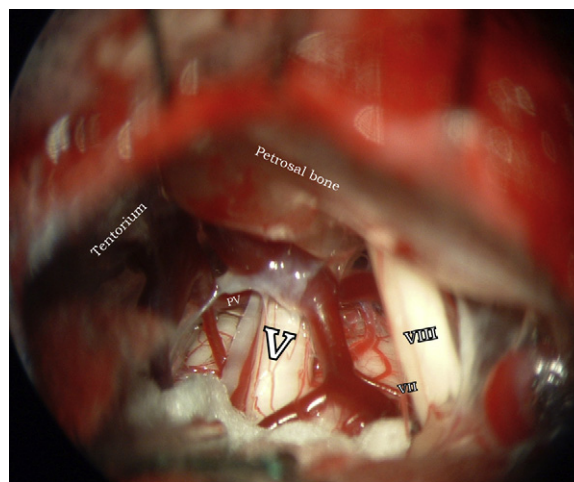


Fig. 1. The offender may locate at any site of the nerve root. In this case, the offender is a petrosal vein (PV) located ventrally to the later trigeminal nerve root (V). VII: facial nerve; VIII: vestibulocochlear nerve.

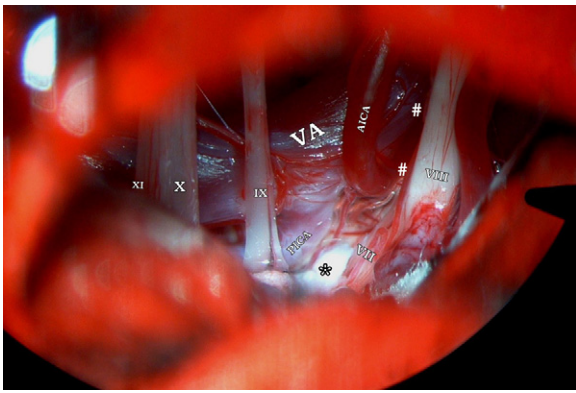


Fig. 2. The dissection should be completed medially enough to expose the pontomedullary sulcus decompression of for facial nerve. In the first operation, the anterior inferior cerebellar artery (AICA) and the vertebral artery (VA) had been regarded as the offending artery at a much lateral area (#). During the reoperation, after the cerebellum was further raised until the pontomedullary sulcus was visualized, the posterior inferior cerebellar artery (PICA) was discovered as the real offender, which was moved away and a Teflon (*) was put between the artery and the nerve. VII: facial nerve; VIII: vestibulocochlear nerve; XI-X-IX: the caudal cranial nerves.

In the redo MVD of 46 TN patients, the real offending artery was found in the lateral root in 27, in medial in 5 and in REZ in 14. Veins were finally found to be the culprit in 17.

3.2. Hemifacial cases

Among the 1327 cases of HFS, the offending vessel was found as the posterior inferior cerebellar artery (PICA) in 51%, AICA in 36%, VA in 10% and vein or unnamed vessel in 3%. The conflict site was discovered at the REZ (where the nerve exits the brainstem) in 93% and at the medial root of the VII cranial nerve in 7%, while no conflict was observed at the lateral root (where the root enters the meatus).

In terms of the mutual locations, the neurovascular conflicts were exhibited as contact in 44%, impress in 46%, adhesion in 8%, and penetration in 2%.

In the redo MVD of 30 HFS, the offending artery was found the rostrally to the VII nerve in 9, between VII and VIII nerves in 9, in the cisternal segment of the VII root in 7 and in the pontomedullary fissure in 15 (9 of them were arterioles).

4. Discussion

MVDs have become a definitive treatment for TN and HFS because it is less invasive and produces excellent results including the preservation of vascular and neural function. With the development of microsurgery, the result of MVD has been improved significantly, but it is still far from a 100% cure rate [13-15]. We believe, theoretically, as long as the offending vessel is moved away from the nerve, the symptom of the patient should be gone. Eventually, we state that a good postoperative outcome is attributed to a reasonable surgical strategy [9,10]. There are some differences between the TN and HFS cases in terms of the operative process. The following points should not be ignored while practicing the surgery.

4.1. Preoperative diagnosis

Characteristic symptoms of TN or HFS are the main evidence of preoperative diagnosis. These symptoms should be differentiated from toothache, migraine and blepharospasm [16]. Magnetic resonance imaging (MRI) may detect the offending vessel(s) in most patients. Yet, it is not the golden standard for diagnosis.

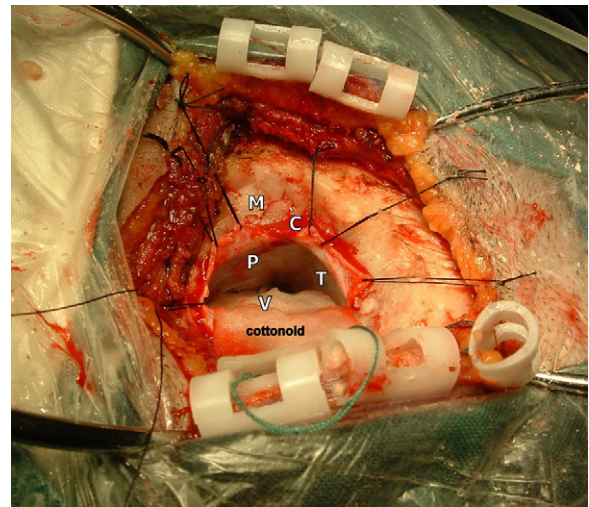


Fig. 3. Intraoperative photo showing the craniectomy and dura opening. This is a left MVD for TN case. Usually, a craniectomy about 2.5 cm in diameter is enough, but the bone work must be lateral enough. Sometimes, part of the posterior mastoid air cells (M) has to drill off (it should be thoroughly waxed) so that no bone overhang will limit the dural opening and reflection. The craniectomy should be rostral enough to reach or even expose the transverse sinus (while it should be low enough to expose the caudal nerves for the HFS cases). It is suggested to open the dura in 'L' shape firstly with the corner at the junction of the transverse and sigmoid sinus (while at the lower outer quadrant in the surgical area for HFS cases). The dura edge along the bone rim should be sutured back after the corner (C) is cut. A cottonoid is placed over the superolateral aspect of the cerebellar surface, which starts the surgical approach from the tentorium (T) toward the petrous bone (P) (while it should start from the caudal nerve toward the facial nerve for the HFS). Notice, in this picture, the trigeminal nerve (V) was virtually visualized before the microscope came in.

Nevertheless, the preoperative MRI may not be neglected, with which some secondary trigeminal neuralgia or facial spasm could be excluded before the surgery. For HFS cases, both VA shifted to the ipsilateral side was often exhibited [17].

4.2. Surgical approach

A good operative position and incision are important to expose the target, which will save time and facilitate the operation. Since the approach trajectory is different between the cases of TN and HFS, the patient's position is different accordingly. As the VII is behind the VIII in the surgical field, the vertex should be inclined down toward the floor as more as possible to expose more proximal aspect of the facial nerve in the HFS cases versus the TN cases. Generally, a craniectomy about 2.5 cm in diameter is enough, but the bone work must be lateral enough. Sometimes, part of the posterior mastoid air cells has to drill off (it should be thoroughly waxed) so that no bone overhang will limit the dural opening and reflection. The craniectomy should be rostral enough to the transverse sinus for the TN cases and low enough to expose the caudal nerves for the HFS cases. We suggested opening the dura firstly in 'L' shape with the corner at the junction of the transverse and sigmoid sinus for the TN case, and at the lower outer quadrant in the surgical area for the HFS case. The dura edge along the bone rim should be sutured back after the corner is cut (Fig. 3). When a surgical microscope comes in, gentle advancement of a moistened cottonoid is required to drain CSF before approaching the target. The cottonoid is placed over the superolateral aspect of the cerebellar surface for the TN case, while inferiolateral for the HFS case. For the TN cases, the surgical approach should start along the tentorium then move down to the petrous bone. Frequently, a couple of petrosal veins may be encountered before the trigeminal nerve is visualized. Sometimes, one or more tributaries of the petrosal vein complex, has to be coagulated and divided to allow

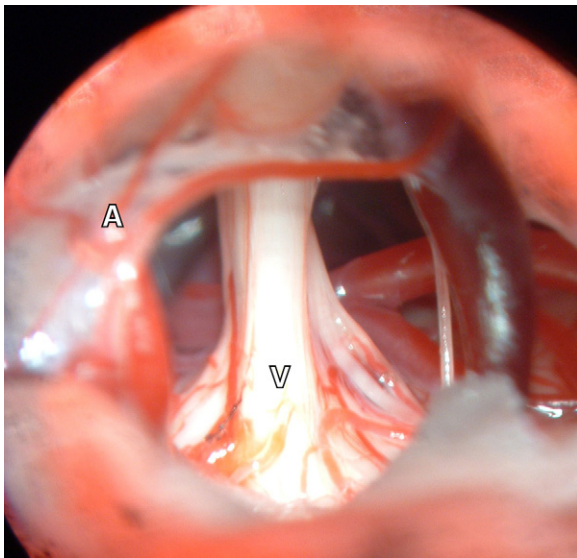


Fig. 4. Upon decompression of the trigeminal nerve (V), arachnoids in the vicinity of the nerve should be opened thoroughly, but any redundant manipulation should be avoided. Notice the arachnoids close to the VII–VIII nerve were intact (A), which protected the nerves from damage imprudently. Compared with the V nerve, the VII–VIII nerves are more delicate.

full visualization of the V cranial nerve. Occasionally, however, it would be a disaster, if the veins were sacrificed *ad libitum* [18]. Therefore, recently we prefer the laterocerebellar to the infratentorial approach, which avoids those block veins [9]. Arachnoid around the trigeminal nerve should be opened thoroughly with microscissors, but not those around the VII–VIII nerves as well as those caudal cranial nerves in most TN cases for the sake of safety (Fig. 4). Contrarily, for the HFS cases, the arachnoid around the caudal nerves should be opened firstly. To discover the offending vessel, the dissection should always go along the caudal nerves rostromedially to the VII–VIII nerve complex.

4.3. Recognition of the offending vessel and decompression of the nerve

If one could predict the conflict site preoperatively, it would facilitate the surgery. It had been believed that the compression must be at the root entry/exit zone of the cranial nerve to cause symptoms. However, at the present study, the conflict was observed almost anyway along the V nerve for TN cases, thought it was mostly at the caudal REZ of the VII nerve for HFS cases. In Sindou's experience of 579 patients with trigeminal neuralgia, the neurovascular compression (one or several per patient) was found at the medial portion of the V nerve or embedded in the pons parenchyma in only 52.3%, midportion of the root in 54.3%, and nearly at the porus of Meckel's cave in 9.8% of patients, while at medial portion of the VII nerve or embedded in the brainstem in 118 of our 120 patients with hemifacial spasm [4]. These findings are concordant with ours. To explain this phenomenon, the histological research of the cranial nerves should be reviewed. A cranial nerve is composed of a central nervous system segment and a peripheral nervous system segment. The central segment has a structure similar to that of white matter of the brain, consisting of parallel traveling nerve fibers. It lacks funicular structure and less vascularized. Conversely, the winding density in the peripheral segment is greater than in the central segment, consisting of undulating nerve fibers, which creates a more elastic and firmer structure. As a result, the peripheral segment of the nerve is more resistant to compression. The central segments of the 12 cranial nerves differ in length.

Basically, motor nerves have a shorter central segment than sensory nerves. According to studies [19], the average length of the central sensory portion of the trigeminal nerve is 2.6 mm, while the length of the central segment of the facial nerve is only 1.7 mm. Eventually, the more length of central portion of the nerve root has the more vulnerable the nerve is. Because the central segment of the trigeminal nerve is longer than that of the facial nerve, logically, the TN patients has more chance of lateral confliction than HFS patients, which is in accordance with published data as well as ours [20–23]. Accordingly, for TN cases, we would check the entire root from pons distally, while focus on the medial portion of the facial nerve for the HFS cases. For TN cases, the most common situation encountered is a long looping SCA compressing the caudal side of the nerve ventromedially. For HFS cases, the more often situation was that AICA or PICA compressed the caudal REZ of the facial nerve. Usually, the conflict was very medial in the pontomedullary sulcus caudally to the caudal nerves (Fig. 2). Sometimes, the culprit could be those arterioles [24]. The decompression should be completed by fully releasing the offending vessel instead of stuffing Teflon. The size of Teflon graft should be appropriate to cause neither new compression nor floating away in the cerebrospinal fluid, which could be placed outside the conflict site. The offending vessel should not be twisted to disturb the blood supply to the brain stem [18].

4.4. Intraoperative electrophysiology

The intraoperative electrophysiological monitoring is helpful to identify the offending vessel for hemifacial spasm cases. From 2010 on, we started to adopt real time monitoring of the abnormal muscle response (AMR) wave. Our published data [9] demonstrated that the AMR vanished after the decompression in 93.9% of the relieved HFS patients. Therefore, we recommend to employ AMR monitoring routinely during the operation for HFS cases.

4.5. For venous compression

Numerous studies have reported [12,25–27] that venous compression might be the main causation of incomplete decompression and symptom recurrence, which is coincidence with our results. Our strategy is to reoperate on the patient in the following day if the symptoms remain. Here is the illustrative case. The patient was a 69-year-old female with 6 years of trigeminal neuralgia. In the first operation, we regarded a bigger petrosal vein as the offending vessel. Regardless the vein was cut and isolated away, the pain symptom was as same as before after the surgery. Therefore, in the next day, we coagulated all the small veins in the REZ thoroughly and the symptom was gone as soon as the patient woke up from the anesthesia (Fig. 5). Nevertheless, when the offending vessel is a large vein, especially it is the only vein that drains into the petrous sinus, it has to be saved. At the present study, all the dead cases were those TN patients and their petrosal veins had been sacrificed in the operation. Sometimes, an occlusion test might be helpful for the decision-making [18].

4.6. Closure

In the early stage, we used to suture the dura with an artificial membrane, which gave rise to considerable CSF leakages. Nowadays, there is no CSF leak anymore, after we have altered to suture the self dura as far as possible. To obtain a watertight closure, sometime a small piece of muscle was used when the native dura is not possible. Finally a duragen was placed over the suture line with glue.

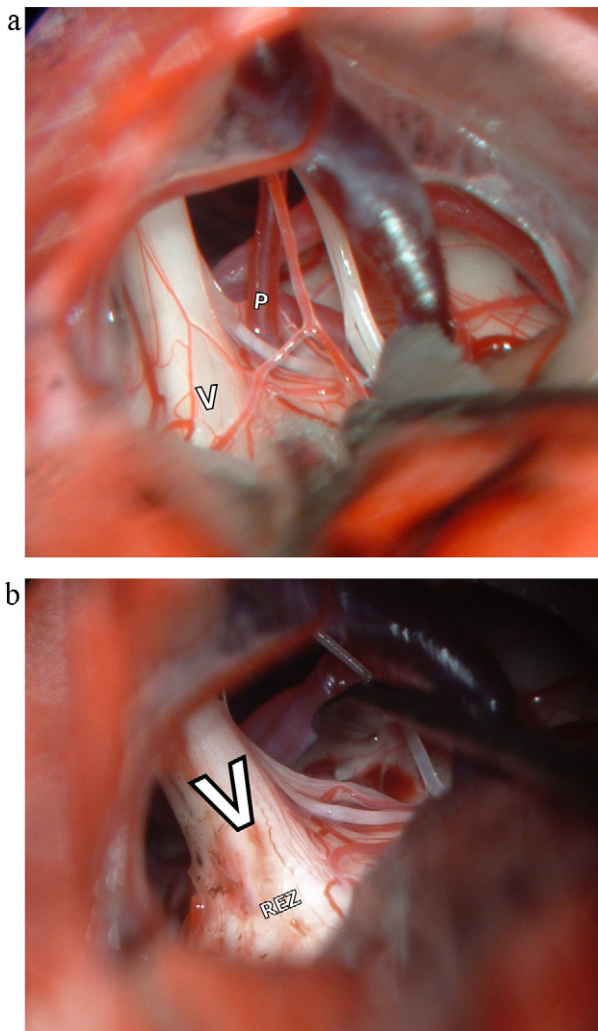


Fig. 5. The venous compression. In the first operation, a petrosal vein (P) penetrating the left trigeminal nerve (V) was regarded as the offending vessel, which was then coagulated and cut, but the pain symptom was as same as before postoperatively (a). Therefore, the patient was reoperated on the next day, and this time all the small veins in the REZ were coagulated thoroughly and the symptom was gone immediately after the surgery (b). Nevertheless, when the offending vessel is a large vein, especially it is the only vein that drains into the petrous sinus, it has to be saved.

4.7. Reoperations

Since this sort of surgery is with risk, we would like to stop the operation if a distinguished vessel compressing the nerve in a frequently haunted area had been detached. For those patients with poor outcome or their symptom even deteriorated postoperatively, we would go through the surgical video recordings repeatedly to check if the entire intracranial nerve root was exposed. If some area seemed to be missed, we would offer the patient a redo MVD promptly as long as the patient requested. In this way, the cure-risk ratio was balanced. Anyway, with enriching experience and assistance of electrophysiology, we did redo MVD less and less recently [22,26].

5. Conclusion

From the above points, we learnt that MVD is an effective treatment for trigeminal neuralgia and hemifacial spasm. A prompt recognition of the offending vessel(s) leads to a successful operation. The neurovascular conflict site could be anyway along the intracranial nerve root rather than just the region of REZ. To obtain

a good microscopic view, the craniotomy should be lateral enough to the sigmoid sinus. For trigeminal neuralgia cases, the whole root of the V nerve from the pons parenchyma to Meckel's cave should be examined – sometime, the offender involved multiple vessels including veins. For hemifacial spasm cases, those arterioles in far more medial zone of the VII nerve in the pontomedullary sulcus should not be neglected.

Disclosure

No disclosure is to be claimed.

References

- [1] Dandy WE. Concerning the cause of trigeminal neuralgia. *Am J Surg* 1934;447-95.
- [2] Jellish WS, Benedict W, Owen K, Anderson D, Fluder E, Shea JF. Perioperative and long-term operative outcomes after surgery for trigeminal neuralgia: microvascular decompression vs. percutaneous balloon ablation. *Head Face Med* 2008;4:11.
- [3] Jannetta PJ, McLaughlin MR, Casey KF. Technique of microvascular decompression. Technical note. *Neurosurg Focus* 2005;18:E5.
- [4] Sindou M, Howeydi T, Acevedo G. Anatomical observations during microvascular decompression for idiopathic trigeminal neuralgia (with correlations between topography of pain and site of the neurovascular conflict) prospective study in a series of 579 patients. *Acta Neurochir (Wien)* 2002;144:1-12 [Discussion 12-13].
- [5] McLaughlin MR, Jannetta PJ, Clyde BL, Subach BR, Comey CH, Resnick DK. Microvascular decompression of cranial nerves: lessons learned after 4400 operations. *J Neurosurg* 1999;90:1-8.
- [6] Kondo A. Microvascular decompression surgery for trigeminal neuralgia. *Stereotact Funct Neurosurg* 2001;77:187-9.
- [7] Wilkinson MF, Kaufmann AM. Monitoring of facial muscle motor evoked potentials during microvascular decompression for hemifacial spasm: evidence of changes in motor neuron excitability. *J Neurosurg* 2005;103:64-9.
- [8] Zhong J, Zhu J, Li ST, Guan HX. Microvascular decompressions in patients with coexistent hemifacial spasm and trigeminal neuralgia. *Neurosurgery* 2011;68:916-20 [Discussion 920].
- [9] Ying TT, Li ST, Zhong J, Li XY, Wang XH, Zhu J. The value of abnormal muscle response monitoring during microvascular decompression surgery for hemifacial spasm. *Int J Surg* 2011;9:347-51.
- [10] Zhong J. A ideal microvascular decompression should be simple a safe. *Neurosurg Rev* 2012;35:137-40.
- [11] Rogers CL, Shetter AG, Fiedler JA, Smith KA, Han PP, Speiser BL. Gamma knife radiosurgery for trigeminal neuralgia: the initial experience of The Barrow Neurological Institute. *Int J Radiat Oncol Biol Phys* 2000;47:1013-9.
- [12] Hong W, Zheng X, Wu Z, Li X, Wang X, Li Y, et al. Clinical features and surgical treatment of trigeminal neuralgia caused solely by venous compression. *Acta Neurochir (Wien)* 2011;153:1037-42.
- [13] Kabatas S, Karasu A, Civelek E, Sabanci AP, Hepgul KT, Teng YD. Microvascular decompression as a surgical management for trigeminal neuralgia: long-term follow-up and review of the literature. *Neurosurg Rev* 2009;32:87-93 [Discussion 93-84].
- [14] Ray DK, Bahgat D, McCartney S, Burchiel KJ. Surgical outcome and improvement in quality of life after microvascular decompression for hemifacial spasms: a case series assessment using a validated disease-specific scale. *Stereotact Funct Neurosurg* 2010;88:383-9.
- [15] Osburn LL, Moller AR, Bhatt JR, Cohen-Gadol AA. Hemilingual spasm: defining a new entity, its electrophysiological correlates and surgical treatment through microvascular decompression. *Neurosurgery* 2010;67:192-5 [Discussion 196].
- [16] Prasad S, Galetta S. Trigeminal neuralgia: historical notes and current concepts. *Neurologist* 2009;15:87-94.
- [17] Guan HX, Zhu J, Zhong J. Correlation between idiopathic hemifacial spasm and the MRI characteristics of the vertebral artery. *J Clin Neurosci: Off J Neurosurg Soc Australas* 2011;18:528-30.
- [18] Zhong J, Li ST, Xu SQ, Wan L, Wang X. Management of petrosal veins during microvascular decompression for trigeminal neuralgia. *Neurol Res* 2008;30:697-700.
- [19] De Ridder D, Moller A, Verlooy J, Cornelissen M, De Ridder L. Is the root entry/exit zone important in microvascular compression syndromes? *Neurosurgery* 2002;51:427-33 [Discussion 433-424].
- [20] Katusic S, Beard CM, Bergstralh E, Kurland LT. Incidence and clinical features of trigeminal neuralgia: Rochester, Minnesota, 1945-1984. *Ann Neurol* 1990;27:89-95.
- [21] Auger RG, Whisnant JP. Hemifacial spasm in Rochester and Olmsted County Minnesota, 1960-1984. *Arch Neurol* 1990;47:1233-4.
- [22] Zhong J, Zhu J, Li ST, Li XY, Wang XH, Yang M, et al. An analysis of failed microvascular decompression in patients with hemifacial spasm: focused on the early reoperative findings. *Acta Neurochir* 2010;152:2119-23.
- [23] Zhong J, Li ST, Zhu J, Guan HX. Is entire nerve root decompression necessary for hemifacial spasm? *Int J Surg* 2011;9:254-7.

- [24] Zhu J, Li ST, Zhong J, Guan HX, Ying TT, Yang M, et al. Role of arterioles in management of microvascular decompression in patients with hemifacial spasm. *J Clin Neurosci* 2012;19:375–9.
- [25] Kimura T, Sako K, Tohyama Y, Yonemasu Y. Trigeminal neuralgia caused by compression from petrosal vein transfixing the nerve. *Acta Neurochir (Wien)* 1999;141:437–8.
- [26] Li S, Hong W, Tang Y, Ying T, Zhang W, Li X, et al. Re-operation for persistent hemifacial spasm after microvascular decompression with the aid of intraoperative monitoring of abnormal muscle response. *Acta Neurochir* 2010;152:2113–8.
- [27] Matsushima T, Huynh-Le P, Miyazono M. Trigeminal neuralgia caused by venous compression. *Neurosurgery* 2004;55:334–7 [Discussion 338–339].