

Hypothalamic Deep Brain Stimulation for the Treatment of Chronic Cluster Headaches: A Series Report

Angelo Franzini, MD*, ■ Paolo Ferroli, MD*, ■ Massimo Leone, MD[†],
■ Gennaro Bussone, MD[†], ■ Giovanni Broggi, MD*

*Departments of *Neurosurgery and [†]Neurology, Istituto Nazionale Neurologico "C. Besta", Milan, Italy*

■ ABSTRACT

The objective of this study was to introduce a new surgical treatment for drug-resistant chronic cluster headaches (CH). Because recent functional studies suggested that a hyperactivity of the posterior hypothalamus might be the primary cause of Cluster Headaches (CH) bouts, we designed a prospective study to explore the therapeutic effectiveness of chronic high-frequency stimulation of this region for the treatment of CH. Nine electrodes were stereotactically implanted in the posterior hypothalamus in eight patients suffering from intractable chronic CH. The stereotactic coordinates of the targeted area were 3 mm behind the mid-commissural point, 5 mm below the mid-commissural point, and 2 mm lateral from the midline. Since initiating this treatment in our center, all of the eight patients have improved. Steroid administration has been progressively withdrawn. All of the patients reported that they were pain-free at 1–26 months of follow-up. Three of the eight patients were pain-free without any medication while five of the eight required low doses of methysergide and/or verapamil. No noxious side effects from chronic high-frequency hypothalamic stimulation have been

observed nor have we encountered any acute complications from the implant procedure. Tolerance was not observed. We conclude that these preliminary results indicate that hypothalamic stimulation is safe and effective for the treatment of drug-resistant, chronic CH. In addition, these data confirm the "central" pathogenesis for chronic CH. ■

KEY WORDS: cluster headache, hypothalamus, neurostimulation, stereotactic surgery.

INTRODUCTION

Chronic cluster headache (CH) is considered one of the most severe facial pain syndromes. Pain can become chronic after several years in an episodic pattern, but CH sometimes appear as a "de novo" disease. Pain usually starts in, around, or above the eye or the temple; occasionally the face, the neck, the ear, or the entire hemicranium may be affected. Attacks usually start with sudden, deep, nonfluctuating pain, excruciating in intensity. Ten to 20 percent of patients report superimposed pain paroxysms in the periorbital region which may occur once or several times in rapid succession. Pain is almost always unilateral, and generally

Address correspondence and reprint requests to: Angelo Franzini, MD, Istituto Nazionale Neurologico "C. Besta", Dipartimento di Neurochirurgia, Via Celoria 11–20133—MILANO. Email: neurochirurgia@istituto-besta.it or bsvjf@tin.it.

affects the same side in subsequent bouts. A shift to the corresponding region of the opposite side is reported in about 15% of patients. Each attack may last from 15 min to 3 h. Attacks range in frequency from eight per 24 h to one per week, with a mean of five to ten per day in severe chronic form in which the attacks may persist for an average of 4–5 years without significant remissions (1). Characteristic features of cluster headache, besides pain, include autonomic symptoms such as lacrimation from the eye on the affected side, rhinorrhea, red eye, and sweating. There is often also an increase in heart rate at the onset of attacks suggesting central autonomic regulatory instability (2–4). Pain attacks may be triggered in nearly all patients by the sublingual administration of 1 mg of nitroglycerin (1).

The pathogenesis of CH still remains to be completely elucidated. CH has been traditionally included in the group of vascular headaches, despite a considerable amount of clinical evidence that has led some authors to hypothesize a central origin. In this view, the vascularity seen during attacks appears to be the result of a primary CNS discharge. Recent neuro-imaging data seem to have identified this alleged central generator of pain attacks within the posterior hypothalamus. Positron emission tomography (PET) revealed activation in the ipsilateral inferior hypothalamic gray matter during CH attacks (5) and morphometric magnetic resonance imaging (MRI) data demonstrated an increase in neuronal hypothalamic density and in hypothalamic size in CH patients (6).

Since the results of surgery for the treatment of medically intractable CH still remain, to this day, disappointing and transitory, alternative strategies for this devastating pain problem are needed (7,8). The analogies between the clinical effects of deep brain stimulation and lesional procedures in the treatment of movement disorders (9) have led us to explore whether surgical electrical interference with this hypothalamic “focus”, evidenced by PET during pain attacks, would benefit patients with the disorder. An extensive review of the literature regarding stereotactic surgical procedures performed within the hypothalamus revealed that Sano (10) had already performed a posterior hypothalamotomy to treat cancer facial pain and that this procedure was safe. Since the Sano target was ipsilateral to the side of the facial pain and

was close to the hypothalamic area, evidenced by PET during CH attacks, we could start from his pioneering experience in our prospective study on the effects of hypothalamic stimulation in CH patients.

MATERIALS AND METHODS

Patients

A multidisciplinary team that included neurologists experienced in the treatment of headache and neurosurgeons with a special interest in functional and stereotactic neurosurgery cooperated in both the evaluation and the selection of patients for the study. The initial diagnosis of CH was made by the neurologist according to the criteria for the diagnosis of chronic CH, as defined under the classification of “Headache” by the International Headache Society (11). The conservative management of these patients consisted of a regimen of the following drugs, alone or in combination: corticosteroids, lithium, methysergide, ergotamine, calcium channel blockers (verapamil), beta-blocking agents, tricyclic antidepressants, valproate, topiramate, gabapentin, melatonin, and nonsteroid anti-inflammatory drugs. In all patients, a transnasal, endoscopic block of the sphenopalatin ganglion was attempted twice prior to considering more invasive surgical procedures. Non-responders were considered candidates for major surgery after at least 1 year without pain remission despite adequate medical treatment. All surgical candidates were screened for psychiatric complications by means of neuropsychological testing and informed of the classic surgical procedures that were available in our Institute for the treatment of intractable CH (open microvascular decompression/lesion of cranial nerves in the cerebellopontine angle and percutaneous radio-frequency trigeminal rhizotomy).

To this date, we have performed stereotactic hypothalamic surgery in eight patients. The first of these was successfully operated on in July 2000 and the results of that surgical procedure have already been reported to the scientific community (12). Since that earlier report, seven additional CH patients have been treated with deep brain ipsilateral hypothalamic stimulation and the baseline data of all eight of these patients are presented in Table 1. Because one patient was experiencing

Table 1. Baseline Clinical Data at Surgery.

Patients	Age	Sex	Side	Bouts per day	Chronic CH duration
1a	39	M	Left	1–4	4 year ^a
1b	39	M	Right	2–5	4 year ^a
2	50	M	Left	3–8	4 year
3	63	F	Left	3–8	7 year
4	52	M	Right	2–8	5 year
5	30	M	Left	4–7	2 year
6	46	M	Left	5–7	2 year
7	27	F	Left	5–7	1 year
8	34	F	Right	6–8	6 year

^aBilateral CH. This patient was first treated with trigeminal radio-frequency rhizotomy on the right side and obtained 10 months of complete pain-relief. During this period he experienced a tremendous exacerbation of left CH with striking oculo-facial vegetative phenomena (4) and received the first implant.

bilateral pain (case 1), an additional contralateral implant was required.

Surgical Technique

Stereotactic implants (Leksell frame, Elekta, Stockholm, Sweden) were performed under local anesthesia. When sedation was required, low doses of midazolam (0.05–0.1 mg/kg) or propofol (0.5–1 mg/kg) were used. Perioperative antibiotics were administered to all patients. A preoperative MRI (brain axial volumetric fast spin echo inversion recovery) was used to obtain high definition anatomic images that allowed for the precise determination of both anterior commissure-posterior commissure line and position and limits of basal ganglia and main mesencephalic nuclei. MR images were fused with 2-mm thick CT slices that were obtained under stereotactic conditions by using an automated technique that is based on a mutual-information algorithm (Frame-link 4.0, Sofamor Danek Stealthstation, Medtronic, Minneapolis, MN). The workstation also provided stereotactic coordinates of the target: 3 mm behind the mid-commissural point, 5 mm below this point, and 2 mm lateral from the midline (Fig. 1). In one case (reported below in detail) this method resulted in a missed target due to the variability of the angle between mesencephalon and the basal ganglia where the mid-commissural point is taken as origin of coordinates for target planning (Fig. 2). A dedicated software is under development to avoid this kind of error from individual variability.

A rigid cannula was inserted through a frontal paramedian burr hole and positioned up to 10 mm from the target. This cannula was used as both a guide for microrecording (Lead Point, Medtronic) and for the placement of the definitive electrode (DBS-3389, Medtronic). Macrostimulation (1–7 V, 60 microsec, 185 Hz) was used to evaluate potential side effects. All patients subjected to stimulus intensities higher than 4 V showed conjugated ocular deviation that was followed by verbal reports of extreme proportions, eg, “I feel near to death”; “I am at the edge of the end”, etc. No pupillary reactions were evoked. When other side effects were ruled out at standard parameters of stimulation, the guiding cannula was removed and the electrode secured to the skull with microplates. An extension cable was then connected to the electrode, tunneled subcutaneously, and brought out of the skin through a stab wound for subsequent trial stimulation. On the day following surgery, an additional MRI study was repeated for the purpose of rechecking the electrode position. After 7–10 days of trial stimulation, the electrodes were connected to a permanent, implanted neuro-pulse generator (Itrel II, Medtronic) which was positioned subcutaneously in the subclavicular area. The following parameters of chronic continuous stimulation were employed: amplitude, 0.5–3.8 V, frequency, 185 Hz, and pulse width, 60 microsec. Voltage was gradually increased up to the therapeutic effect. The effects of changes in frequency and pulse width were not investigated.

After the electrode implantation, stimulation was not started immediately; it was started after CH attacks appeared on daily basis.

RESULTS

The results of this study are presented in Table 2. All patients achieved complete pain relief as a result of the long-term high-frequency hypothalamic stimulation that continued until last follow-up evaluation (2–26 months). Complete pain relief was achieved by progressive reduction in number of daily attacks until the disappearance of any symptoms over an average period of 4.4 weeks. Three of eight patients remained pain-free without medication (cases 1, 5, and 6), while five of eight patients had attacks from time to time (less than five per month) with low doses of methysergide

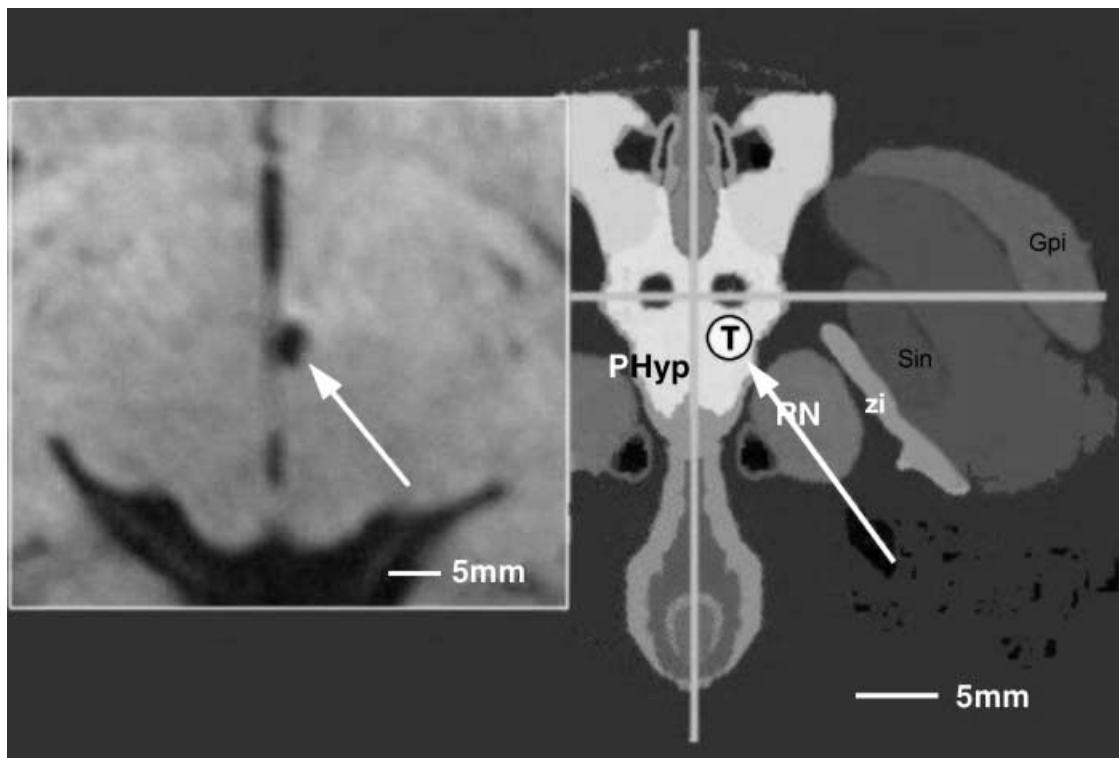


Figure 1. The target for treatment of cluster headache by deep brain neurostimulation. **Left:** postoperative MRI axial slice of Case 3 with the electrode at the proper target pointed by the arrow. **Right:** Stereotactic atlas registered to the intercommissural line. The represented axial slice is 5 mm below the commissural plane. The center of the cross is the projection of the intercommissural line midpoint. The arrow points the target area (T) within the posterior hypothalamus as reconstructed and modified from the Van Buren and Borke stereotactic atlas (20).

or verapamil. It should be noted that these same drugs had been completely ineffective prior to this operative procedure. No patient benefited from electrode implantation until stimulation was started.

We observed no noxious side effects from chronic high-frequency hypothalamic stimulation nor did we observe any acute complications from the implant procedure.

Importantly, there was no clinical evidence of autonomic effects of hypothalamic stimulation observed during either acute preoperative electrical stimulation or during chronic therapeutic stimulation. Twenty-four hour, continuous monitoring of arterial blood pressure revealed only asymptomatic orthostatic hypotension triggered by the electrical stimulation in four patients, monitored before and after surgery. Heart rate was not affected by neurostimulation. The absence of clinical evidence for autonomic effects from posterior deep brain stimulation of the hypothalamus, however, does not necessarily mean that there are none. In our opinion, careful instrumental analysis of autonomic

functions might possibly be needed to identify any autonomic dysfunction related to this stimulation.

We had to turn off the stimulator in two cases and this resulted in prompt reappearance of CH attacks, but restoration of stimulation abolished, once again, the painful symptoms. Tolerance to stimulation was not seen in our series. Two cases deserve a detailed description because their clinical history is highly important in the definition of both the mechanism of action and target location.

Case reports

Case 1

This is a report of the first patient who underwent hypothalamic chronic stimulation for CH who required a contralateral implant because of bilateral CH. This 39-year-old right-handed man had been suffering from CH (2–5 attacks per day) since 1997. Striking oculo-facial autonomic phenomena were associated with these attacks. This patient's pain and associated symptoms were refractory to

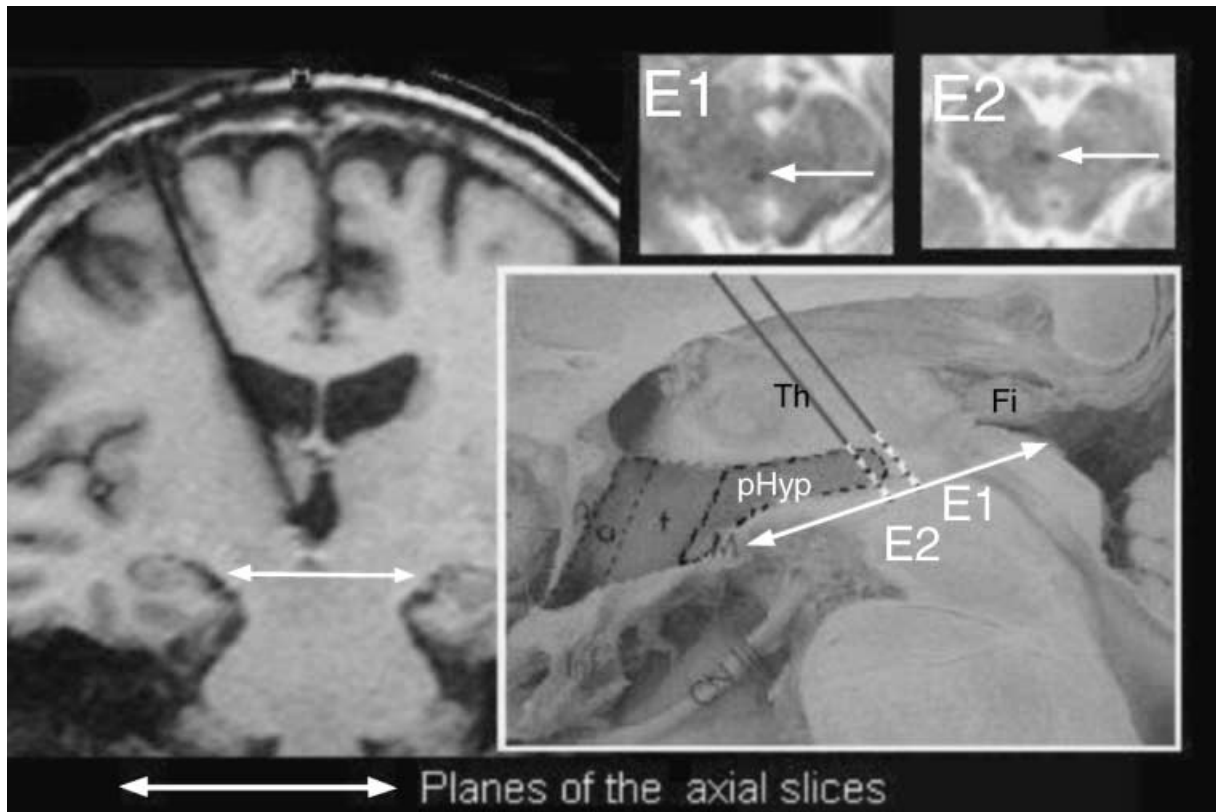


Figure 2. Schematic representation of Case 2 reported in the text. Demonstration of the posterior boundaries of the target for the treatment of CH by deep brain neurostimulation. **Left:** MRI coronal section with the electrode at the proper target. The white line with arrows indicates the plane of axial sections corresponding to the tip of the electrode (E2 at upper right). **Upper right:** E1: MRI axial section showing the tip of the electrode before the replacement; the patient had only a mild decrease of CH bouts daily rate in spite of high frequency stimulation. Note the close relationships to the periaqueductal gray matter. E2: MRI axial section showing the tip of the electrode after the replacement in a more anterior target toward posterior hypothalamus: CH bouts disappeared with high-frequency stimulation. Both MRI slices show the tip of the electrode within the mesencephalon (8 mm below the commissural plane). The active contact is higher (5 mm below the commissural plane as shown in Fig. 1 and in the anatomical reconstruction). **Lower right:** Reconstruction of the electrode position in a sagittal anatomical plate, note that the replaced electrode with therapeutic effects (E2) crosses the tail of posterior hypothalamus (Phyp) while the previous ineffective electrode (E1) is just at the boundaries of hypothalamus.

verapamil, lithium, methysergide, ergotamine, tricyclic antidepressants, melatonin, nonsteroid anti-inflammatory medications, antiepileptic drugs, and high-dosage intravenous dexamethasone. Ninety percent of the attacks were on the right side and two consecutive radiofrequency trigeminal rhizotomies were successful in obtaining pain relief. Unfortunately, as soon as his pain attacks disappeared on the right side, they worsened on the left side, where, as already reported to the scientific community, chronic stimulation of the ipsilateral posterior hypothalamus (electrode implant on July 14, 2000) produced complete pain relief. Eight months after radiofrequency trigeminal rhizotomies, his right-sided, drug-refractory pain attacks

recurred at a frequency of three to eight per day, demonstrating that the effect of his left chronic hypothalamic stimulation was strictly ipsilateral. After informed consent, a mirror stereotactic implant in the right posterior hypothalamus was performed on May 31, 2001. Since the situation on the right side was dramatic, continuous stimulation was immediately started and after 24 h, right-sided attacks disappeared at the following parameters of stimulation: amplitude: 0.5 V, pulse width, 60 micro-sec, frequency 185 Hz, and programmed unipolar stimulation with hypothalamic contacts. At last follow-up, under continuous bilateral deep brain stimulation, the patient was still pain-free without medication. His associated autonomic phenomena

Table 2 Results of Surgery (Follow-up: 2–26 months).

Patients	Date of surgery	Complete pain-control	Side effects
1a	July 2000	After 4 weeks	Decrease of food intake ^a
1b	May 2001	Immediate	None
2	November 2000	After 10 weeks	None
3	May 2001	After 8 weeks	None
4	October 2001		
	July 2002 reimplantation	After 3 weeks	None
5	March 2002	After 5 weeks	None
6	May 2002	After 5 weeks	None
7	September 2002	After 4 weeks	None
8	November 2002	After 1 week	None

^aProbably related to high dosage, long-term, steroid course discontinuation.

were also well controlled by stimulation. No side effects from both unilateral and bilateral stimulation were observed. He presented with signs of both mild hypersexual and hyperphagic behavior prior to the operation which seemed to be resolved by stimulation. In fact, this patient showed a 25-kg weight loss at the 18-month follow-up. This case demonstrates that the effect of stimulation is strictly ipsilateral, despite the fact that the target localization is very close to the midline.

Case 4

This case exemplifies a missed target and the definitions of the posterior limit of the therapeutic area. This 52-year-old right-handed man had been suffering with chronic CH (4–8 attacks per day) since 1997. Pain attacks were refractory to verapamil, lithium, methysergide, ergotamine, tricyclic antidepressants, melatonin, valproate, topiramate, and nonsteroid anti-inflammatory medications. Only continuous administration of 8 mg per day of intramuscular dexamethasone reduced his attack frequency from four to eight per day to one to two per day. On October 11, 2001 a stereotactic electrode implant in the right posterior hypothalamus was performed. After 6 months of continuous chronic stimulation, a 20% reduction in frequency of daily bouts was obtained using the following parameters of stimulation: amplitude, 3.8 V; pulse width, 60 microsec; and frequency, 185 Hz. The electrode coordinates in a midpoint-based CA-CP Cartesian system resulted in the electrode being 4 mm posterior to the optimal estimated target on the postoperative MRI (Fig. 2). Due to the better outcome observed in patients with a more anterior placement, a stereotactic electrode replacement

procedure was performed on June 24, 2002 (Fig. 2). A marked reduction of pain attacks was reported by the patient a few days following surgery. Parameters of stimulation were amplitude, 1.4 V; pulse width, 60 microsec; and frequency, 185 Hz. At last follow-up, the patient was still pain-free without concomitant medication use, and was using continuous deep brain stimulation with the same parameters. This case shows that the therapeutic area has a clear-cut posterior boundary.

DISCUSSION

The management of CH should be primarily medical and not surgical. Unfortunately, there are some patients that do develop a form of chronic, unremitting CH that is refractory to any medical management, including long-term corticosteroids treatment. To date, a remarkably broad range of pharmacologic agents are being used to treat CH. These medications include methysergide, corticosteroids, ergotamine, lithium, melatonin, calcium channel blockers (verapamil), valproate, topiramate, gabapentin, indomethacin, as well as triptans and oxygen inhalation agents. These patients do pose a very real challenge to the scientific community. In fact, it would not be overstating the case to say that the operative treatment of CH remains a most frustrating endeavour. Surgical treatment is based on the interruption of the autonomic pathways (greater superficial petrosal nerve, intermedius nerve section, sphenopalatine ganglion lesions) and/or, on a partial or total trigeminal lesion (thermal rhizotomy, glycerolysis, direct nerve sectioning, peripheral avulsions) (7,8,13–15). There appears, however, to be a direct

relationship between sensory deficit (and subsequent discomfort with facial numbness, keratitis, dysesthesia, and sometimes anesthesia dolorosa) and success rate. In addition to these troubling side effects, the recurrence rate of CH remains high and even a complete trigeminal deafferentation can be followed by the persistence of attacks of CH (16). Microvascular decompression of the trigeminal and facial nerves represent the only attempts, thus far, to obtain pain relief without lesioning the central nervous system. Unfortunately, the long-term results of these procedures continue to be quite disappointing (17).

Although the pathophysiology of CH still remains poorly understood, historically and traditionally it has been considered and treated as having a peripheral vasogenic origin. However, the fact that there is a circadian rhythm associated with the symptoms of CH casts doubt on a purely vasogenic origin. Recent functional and morphologic studies shed light on a new pathophysiologic process to explain CH, in which a central mechanism that involves the hypothalamus plays a primary role. May et al. using PET to assess the changes of regional cerebral blood flow during nitroglycerine-induced CH attacks (5) found a hypothalamic activation in CH patients during bouts that was not seen in CH patients when bouts were not present. Additionally this same group found morphometric and structural abnormalities in the hypothalamic region of CH patients (6), a finding that further supports the hypothesis of a central origin of the disease. If a central dysfunction involving hypothalamic circuitry is linked to CH, it seems reasonable to question whether surgical strategies may be used to rebalance unbalanced or disturbed circuits. According to current models of basal ganglia circuitry, the akinetic and rigid symptoms of Parkinson's disease (PD) result from hyperactivity of the globus pallidus internus and substantia nigra pars reticulata, a consequence of an increased glutamatergic drive from a disinhibited subthalamic nucleus (STN). Even if the mechanism of high-frequency, deep brain stimulation remains unknown, the therapeutic effect found after long-term, high-frequency deep brain stimulation in PD seems to be a result of the inhibitory effect of current delivery to STN hyperactive neurons (9). Using the same kind of logic, we now suggest that a similar mechanism may account for

our preliminary success with the use of deep brain hypothalamic stimulation in CH patients. It is suggested that a hyperactive hypothalamus may be playing a role in chronic CH. Though our results are consistent with the hypothesis that a rebalancing of a hyperactive hypothalamus is responsible for the therapeutic effect we observe, we cannot rule out a more generic analgesic effect that is coming from an activation of some pain modulating pathway or pathways, such as the one involving the release of endogenous opiates. However, there are at least four reasons that we can think of that counter this notion:

- 1 the effect of stimulation is strictly lateralized (case 1);
- 2 moving the target posteriorly, towards the periventricular gray, results in a decrease of efficacy of stimulation (Fig. 2) which was, on the contrary, very effective when the electrode was correctly placed in the posterior hypothalamus;
- 3 the fact that in CH patients opiates are not effective;
- 4 the prolonged duration of the pain relief that we have observed, devoid of the development of tolerance that has been seen in patients undergoing periaqueductal gray matter stimulation for chronic pain of different origin (18).

Surgical procedures on the posteromedial hypothalamus have been published by Sano (10) to treat behavioral disorders such as violence and aggression as well as to relieve malignant facial pain. These same authors have also published findings in which intraoperative high-frequency stimulation of the hypothalamus has been used to target a lesion area. In that report they found analgesic effects, autonomic responses such as hypertension, tachycardia, respiratory suppression, hyperpnea, tachypnea, and mydriasis, as well as somatomotor responses. No such effects were observed in our series of CH patients, probably because of differences in both the targeting and the stimulation parameters that have been used.

CONCLUSIONS

To the authors' knowledge, this is the largest series reported involving the successful treatment of patients with chronic CH using long-term,

high-frequency hypothalamic stimulation. These preliminary results provide evidence to suggest that hypothalamic stimulation might offer a safe and effective treatment for CH without any of the troublesome side effects associated with lesioning procedures. Chronic stimulation of the posterior hypothalamus appears to be safe and effective even when used bilaterally. The therapeutic rationale for our work is grounded on more advanced functional studies that identify the hypothalamus as the “primum movens” of CH attacks. We suggest that the abolition of CH attacks we obtained may be due to a stimulation-induced rebalancing of hyperfunctioning, hypothalamic neurons, a hypothesis which further supports the central origin of CH (19). The fact that the therapeutic effect is strictly confined to the ipsilateral side of stimulation seems to rule out a more non-specific neuro-modulatory pharmacologic-like effect, mediated by the antinociceptive system. The central pathogenic role of the posterior hypothalamus is evidenced by the case that we have illustrated, where an electrode placement closer to the PAG-PVG system (more posterior in the midbrain-diencephalic junction) was less effective than when placed into our usual target area. Finally, it should also be noted that this, to our knowledge, is the first direct therapeutic application of neuro-imaging functional data to lead to a restorative-reversible approach to this kind of a disabling condition.

ACKNOWLEDGMENT

We thank heartily Dr. Allen Ferziger (Adjunct Professor, Honors Department, University of Maryland) for assistance in revising the manuscript.

REFERENCES

1. Ekbom K, Hardebo JE. Cluster headache: aetiology, diagnosis and management. *Drugs* 2002;62:61-69.
2. Manzoni GC, Micieli G, Granella F, Tassorelli C, Zanferrari C, Cavallini A. Cluster headache — course over ten years in 189 patients. *Cephalalgia* 1991 September;11:169-174.
3. Kudrow L. Diagnosis and treatment of cluster headache. *Med Clin North Am* 1991;75:579-594.
4. Leone M, Bussone G. A review of hormonal findings in cluster headache. Evidence for hypothalamic involvement. *Cephalalgia* 1993;13:309-317.
5. May A, Bahra A, Buchel C, Frackowiak RS, Goadsby PJ. Hypothalamic activation in cluster headache attacks. *Lancet* 1998;352:275-278.
6. May A, Bahra A, Buchel C, Frackowiak RJS, Goadsby PJ. PET and MRA findings in cluster headache and MRA in experimental pain. *Neurology* 2000;55:1328-1335.
7. Sweet WH. Surgical treatment of chronic cluster headache. *Headache* 1988;28:669-670.
8. Broggi G, Franzini A, Ferroli P. Cluster headache: role of surgery. *Ital J Neurol Sci* 1999;20 (Suppl. 2):75-79.
9. Benazzouz A, Gross C, Feger J, Boraud T, Bioulac B. Reversal of rigidity and improvement in motor performance by subthalamic high-frequency stimulation in MPTP-treated monkeys. *Eur J Neurosci* 1993;5:382-389.
10. Sano K, Mayanagi Y, Sekino H, Ogashiwa M, Ishijima B. Results of stimulation and destruction of the posterior hypothalamus in man. *J Neurosurg* 1970;33:689-707.
11. Headache Classification Committee of the International Headache Society. Classification and diagnostic criteria for headache disorders, cranial neuralgia and facial pain. *Cephalalgia* 1988;8 (Suppl. 7):1-96.
12. Leone M, Franzini A, Bussone G. Stereotactic stimulation of posterior hypothalamic gray matter in a patient with intractable cluster headache. *N Engl J Med* 2001;345:1428-1429.
13. Mathew NT, Hurt W. Percutaneous radiofrequency trigeminal gangliorhizolysis in intractable cluster headache. *Headache* 1988;28:328-331.
14. Mathew NT. Cluster headache. *Neurology* 1992;42 (Suppl. 2):22-31.
15. Maxwell RE. Surgical control of chronic migrainous neuralgia by trigeminal gangliorhizolysis. *J Neurosurg* 1982;57:459-466.
16. Matharu MS, Goadsby PJ. Persistence of attacks of cluster headache after trigeminal nerve root section. *Brain* 2002;125:976-984.
17. Lovely TJ, Kotsiakos X, Jannetta PJ. The surgical management of chronic cluster headache. *Headache* 1998;38:590-594.
18. Broggi G, Franzini A, Giorgi C, Spreafico R. Preliminary results of specific thalamic stimulation for deaf-ferentation pain. *Acta Neurochir* 1984;33 (Suppl.):497-500.
19. Goadsby PJ, May A. Mechanisms of cluster headache. *Cephalalgia* 1999;19 (Suppl. 23):19-21.
20. Van Buren JM, Borke RC. *Variations and Connections of the Human Thalamus: 2. Variations of the Human Diencephalon*. Berlin: Springer, 1972.