

See discussions, stats, and author profiles for this publication at: <https://www.researchgate.net/publication/9017126>

Central neuromodulation in chronic migraine patients with suboccipital stimulators: A PET study

Article in *Brain* · January 2004

DOI: 10.1093/brain/awh022 · Source: PubMed

CITATIONS

429

READS

68

6 authors, including:



Manjit S Matharu

University College London

110 PUBLICATIONS 4,680 CITATIONS

[SEE PROFILE](#)



Nick S Ward

University College London

119 PUBLICATIONS 7,175 CITATIONS

[SEE PROFILE](#)



Richard Frackowiak

École Polytechnique Fédérale de Lausanne

740 PUBLICATIONS 126,158 CITATIONS

[SEE PROFILE](#)

Some of the authors of this publication are also working on these related projects:



functionnal organisation of the human auditory cortex [View project](#)



Human Brain Project [View project](#)

Central neuromodulation in chronic migraine patients with suboccipital stimulators: a PET study

Manjit S. Matharu,¹ Thorsten Bartsch,¹ Nick Ward,² Richard S. J. Frackowiak,² Richard Weiner³ and Peter J. Goadsby¹

¹Headache Group and ²Wellcome Department of Imaging Neuroscience, Institute of Neurology and The National Hospital for Neurology and Neurosurgery, Queen Square, London, UK and ³Department of Neurosurgery, Presbyterian Hospital of Dallas, Dallas, Texas, USA

Correspondence to: Professor Peter J. Goadsby, Institute of Neurology, Queen Square, London WC1N 3BG, UK
E-mail: peterg@ion.ucl.ac.uk

Summary

Electrical stimulation of primary sensory afferents is known to have an antinociceptive effect. Animal and functional imaging studies suggest a role for supraspinal structures in this response. **Eight patients with chronic migraine** (≥ 15 days per month of attacks of migraine without aura), **who had shown a marked beneficial response to implanted bilateral suboccipital stimulators, were studied. Stimulation evoked local paraesthesia, the presence of which was a criterion of pain relief. On stimulation, the headache began to improve instantaneously and was completely suppressed within 30 min. On switching off the stimulation, the headache recurred instantly and peaked within 20 min. PET scans were performed using regional cerebral blood flow (rCBF) as a marker of neuronal activity. Each patient was scanned in the following three states: (1) stimulator at optimum settings: patient pain-free but with paraesthesia; (2) stimulator off: patient in pain and no paraesthesia;**

(3) stimulator partially activated: patient with intermediate levels of pain and paraesthesia. All scans were processed and analysed using Statistical Parametric Mapping (SPM) 99. **There were significant changes in rCBF in the dorsal rostral pons, anterior cingulate cortex (ACC) and cuneus, correlated to pain scores, and in the ACC and left pulvinar, correlated to stimulation-induced paraesthesia scores.** The activation pattern in the dorsal rostral pons is highly suggestive of a role for this structure in the pathophysiology of chronic migraine. The localization and persistence of activity during stimulation is exactly consistent with a region activated in episodic migraine, and with the persistence of activation of that area after successful treatment. The dorsal rostral pons may be a locus of neuromodulation by suboccipital stimulation. In addition, suboccipital stimulation modulated activity in the left pulvinar.

Keywords: headache; migraine; periaqueductal grey; pons; pulvinar

Abbreviations: ACC = anterior cingulate cortex; CDH = chronic daily headache; GON = greater occipital nerve; IHS = International Headache Society; PAG = periaqueductal grey; PET = positron emission tomography; rCBF = regional cerebral blood flow; VRS = verbal rating scale

Introduction

Chronic daily headache (CDH), defined as headache occurring on 15 days or more a month, is a widespread problem in neurological practice. Population-based studies in the USA (Scher *et al.*, 1998), Europe (Castillo *et al.*, 1999; Lanteri-Minet *et al.*, 2003) and Asia (Wang *et al.*, 2000) suggest that 4–5% of the general population have CDH. Chronic migraine is a subset of CDH in which daily or near-daily headaches occur, some of which are accompanied by migrainous features (Welch and Goadsby, 2002). Diagnostic criteria have been proposed (Silberstein *et al.*, 1996), and chronic migraine is now recognized as a distinct entity in the revised

International Headache Society (IHS) classification (Headache Classification Committee of The International Headache Society, 2004). In population-based surveys, chronic migraine occurs in 1.3–2.4% of the population (Scher *et al.*, 1998; Castillo *et al.*, 1999; Lanteri-Minet *et al.*, 2003).

Migraine is a form of primary neurovascular headache that is likely to be based on dysfunction in the brain (Goadsby *et al.*, 2002). PET in primary headaches, such as migraine (Weiller *et al.*, 1995) and cluster headache (May *et al.*, 1998a, 2000), has demonstrated activations in brain areas associated

with pain, such as the cingulate cortex, insulae, frontal cortex, thalamus, basal ganglia and the cerebellum. These areas are similarly activated when head pain is induced by injection of capsaicin into the forehead of volunteers (May *et al.*, 1998b). In addition to these generic pain areas, activations in specific brain regions can be seen in episodic migraine that are not observed when the first (ophthalmic) division pain pathways are activated by the capsaicin injections. Specifically, brainstem areas are activated in episodic migraine (Weiller *et al.*, 1995), one of which was recently refined in localization to the dorsal pons (Bahra *et al.*, 2001). The underlying pathophysiology of chronic migraine is likely to be similar to that of episodic migraine, with brainstem activation, perhaps continuously.

Data on the prognosis of optimally managed chronic migraine are limited. The literature on CDH managed in headache centres, where the majority of CDH patients have chronic migraine (Silberstein *et al.*, 1996), shows that 49–91% of the patients do well (Silberstein and Lipton, 2001). Hence a significant minority of patients continue to have intractable headaches despite optimum therapy; this is in keeping with our experience.

We report eight patients with the IHS diagnosis of chronic migraine who have shown a marked beneficial response to implanted bilateral suboccipital stimulators. We sought to understand the central mechanisms that underpin this antinociceptive effect of implanted suboccipital stimulators by performing a PET study. We sought to determine the brain structures active in chronic migraine and how they are modulated by suboccipital stimulation with regional cerebral blood flow (rCBF) PET as an index for neuronal activity (Frackowiak and Friston, 1994). We hypothesized, based on the literature, that suboccipital stimulation would involve the periaqueductal grey (PAG), thalamic nuclei, particularly the pulvinar, the anterior cingulate cortex (ACC) and the insula. In addition, we hypothesized that the pain of chronic migraine would involve the dorsal rostral pons, thalamus, ACC and insula.

Methods

General methods and suboccipital stimulators

Eight right-handed patients (age 32–53 years, mean 44 years; seven female, one male) with the IHS diagnosis of chronic migraine (Headache Classification Committee of The International Headache Society, 2004) as the underlying phenotype, who had implanted bilateral suboccipital stimulators, were studied. In six patients the onset of chronic migraine was associated with trauma; in the other two it evolved from episodic migraine. We have classified the patients based on their headache phenotype as having symptoms consistent with chronic migraine in the new IHS diagnostic criteria (Headache Classification Committee of The International Headache Society, 2004). Individual cases are outlined below in summary, detailed descriptions being available from the authors.

The stimulators (Medtronic Synergy®/Irel®; Medtronic, MN, USA) were implanted subcutaneously at the Department of Neurosurgery, Presbyterian Hospital of Dallas, USA (Weiner and

Reed, 1999; Weiner, 2002). The tips of the electrodes were positioned superficial to the cervical muscular fascia and transverse to the greater occipital nerve (GON) trunk at the level of the first cervical spine. The stimulation settings were individually chosen by the patients according to the pain relief; the pulse width ranged from 90 to 180 μ s, the frequency ranged from 60 to 130 Hz and the amplitude from 1.5 to 10.5 V. The area of paraesthesia during stimulation was restricted to the area adjacent to the implanted electrodes in the distribution of the GON.

Informed consent was obtained from all patients and the study was approved by the Ethics Committee of the National Hospital for Neurology and Neurosurgery, London, UK and the Presbyterian Hospital of Dallas, TX, USA. Permission to administer radioactivity was obtained (Administration of Radioactive Substances Advisory Committee of the Department of Health, UK).

Case material

Case 1

A 53-year-old, right-handed woman presented with an 8-month history of daily headaches in September 2000. For 25 years prior to the onset of the daily headaches, she had had episodic headaches which satisfied the IHS criteria for migraine without aura (Headache Classification Committee of The International Headache Society, 2004). In January 2000, she slipped on ice and fell backwards, hitting the back of her head on the floor. On regaining consciousness after 15 min, she had amnesia for the event, a severe headache, loss of vision in the right visual field and mild left hemiparesis, manifesting as poor left-hand fine-finger movements and left-sided clumsy gait. An MRI scan of the head was normal. Vision recovered completely over the next 2 months. The left hemiparesis has remained unchanged.

She described a bilateral headache that started immediately after the head injury and persisted. It was worse on the right than on the left and centred on the occiput. The headache was constant, severe, and had a pulsating quality. It was associated with nausea, vomiting, photophobia, phonophobia, osmophobia and worsening with movement. It was also associated with bilateral nasal blockage and rhinorrhoea. She frequently had aura symptoms, which lasted 30–60 min, particularly when the intensity of the headache peaked. The headache could be exacerbated by psychological stress and bright lights. In the family history, her mother, son and daughter suffered from migraine. Neurological examination revealed a hypoaesthetic area in the GON dermatome. There were no cervical or occipital trigger points and no tenderness. Cranial nerve examination was normal except for a partial right Horner's syndrome. Motor examination revealed difficulty with fine finger movements in the left hand, though power testing was otherwise normal in the upper limbs. There was mild weakness of left knee flexion and ankle dorsiflexion.

In September 2000, bilateral suboccipital stimulators were sited. They have been highly effective, consistently rendering the patient pain-free within 5–10 min. The patient has been able to stop all headache abortive and preventive medications.

Case 2

A 43-year-old, right-handed woman developed daily headaches in May 1995 following a road traffic accident. At presentation she described a bilateral headache, which was worse on the right than on the left. It was centred on the occiput with radiation to the parietal

region, temple, retro-orbital and orbital region, and the neck. It was very severe in intensity and had a throbbing or tightening quality. It was associated with nausea, photophobia, phonophobia and osmophobia, and worsened with movement and bilateral conjunctival injection. She denied vomiting, any symptoms of a migraine aura or any other cranial autonomic features. The headache could be triggered by over sleeping, lack of sleep, over exertion, changes in barometric pressure, emotional stress, driving in a motor vehicle, and a noisy environment.

In 1999 she had bilateral GON blocks and bilateral supra-orbital blocks, with which she received 6 h of pain relief. There was no family history of headaches. Neurological examination was unremarkable.

In August 2001 bilateral suboccipital stimulators were implanted with which there was a moderate improvement in the headache. In September 2001 temporary implants were placed over the supra-orbital region, which further reduced the pain to mild intensity. In October 2001, permanent supra-orbital stimulators were sited bilaterally. She has managed to completely stop all analgesics and headache preventive medications.

Case 3

A 44-year-old, right-handed man presented with a history of headaches since his teenage years. He described bilateral headaches centred on the forehead with radiation to the temples. They were severe in intensity and had a throbbing quality. These headaches were associated with worsening on movement and bilateral lacrimation. He denied nausea, vomiting, photophobia, phonophobia, osmophobia and any symptoms suggestive of a migrainous aura or any other cranial autonomic features. A typical episode lasted 1–3 days. It occurred 1–2 times annually.

In 1991, his headaches began to increase in frequency and duration such that by 1996 he had a daily, constant headache. At presentation in July 2000, he described a bilateral headache, worse on the right than on the left. It was centred on the occiput with radiation to the vertex, parietal region and the forehead. On 5–15 days per month he had a background headache, which was moderate in severity, had a throbbing quality and was associated with mild nausea, photophobia and worsening with movement. On the remaining 15–25 days he had an exacerbation which was very severe in intensity and had a burning, stabbing or throbbing quality. It was associated with nausea, vomiting, photophobia, osmophobia and worsening with movement. He denied photophobia, any symptoms suggestive of migrainous aura or any cranial autonomic features. The exacerbations could be triggered by lack of sleep, over sleeping, over exertion and bright lights. Infrequently and inconsistently, neck movement could trigger a headache. C₂ blockade provided relief for a few days, as did bilateral GON blocks.

Detailed neurological examination was entirely normal except for hypoaesthesia over the GON distribution bilaterally.

In August 2000 a right-sided suboccipital stimulator was sited. There was marked benefit: the headache improved on both sides. In October 2000, a left suboccipital stimulator was sited. When the stimulators are switched on, the patient is rendered pain-free within 5 min.

Case 4

A 45-year-old, right-handed female presented with a history of daily headaches since May 1993, when she slipped on ice and fell

backwards, landing on her occiput and back. At presentation, on 10 days per month she had a mild background headache or was pain-free, while on the remaining 20 days per month she had an exacerbation. The background headache was holocranial, mild in severity, with a tightening quality. The exacerbation was bilateral, centred on the occipital region with radiation to the vertex, temple and the forehead. It was severe in intensity and had a pulsating quality. It was associated with nausea, vomiting, photophobia, phonophobia, worsening with movement, nasal blockage and lacrimation. The headache could be triggered by over exertion, lack of sleep, over sleeping, bright lights and barometric pressure changes. In the family history, her son and an aunt have migraine.

Neurological examination revealed a hypoaesthetic area confined to the distribution of the GON. Bilateral suboccipital stimulators were sited in 2000, and have been highly effective. On switching on the stimulator, symptoms begin to improve immediately and the patient is pain-free within 20 min.

Case 5

A 46-year-old, right-handed woman presented in early 2002 with a history of daily headaches since 1999. She had migraine without aura between the ages of 12 and 16 years. Since 1999 she has had daily headaches. At presentation, on 5–10 days per month she had a background headache, which was holocranial, mild to moderate, and of tightening quality. On the remaining 20–25 days per month, she had a severe bilateral headache, worse on the right than the left, starting over the forehead and temple before becoming holocranial. The headaches were throbbing, pressing or tightening in quality. They were associated with photophobia, phonophobia, osmophobia, worsening with movement and lightheadedness. She also reported bilateral lacrimation, nasal blockage and facial sweating in association with the headaches. She denied nausea, vomiting and any other cranial autonomic features. On 10 days per month the headache occurred in association with a sensory aura lasting 30 min. The headaches could be triggered by dietary factors (chocolate, cheese and monosodium glutamate), alcohol, over exertion and lack of sleep. In the family history, her daughter suffers from migraine. Neurological examination was unremarkable.

In April 2002, bilateral suboccipital stimulators were sited. The procedure was complicated by the development of a self-limiting abdominal haematoma. The stimulator is highly effective, rendering the patient pain-free within 5 min.

Case 6

A 32-year-old, right-handed woman presented in early 2002 with a history of daily headaches since mid-2000. She had infrequent migraine with aura during her childhood and teenage years. Since mid-2000 she had had daily, constant headaches, and two car accidents in the late 1990s produced associated increases in headache frequency. At presentation, she had a constant background headache on 10–15 days per month and a superimposed exacerbation on 15–20 days per month. The background headache was bilateral, holocranial, mild to moderate in severity, and had a tightening quality. It was featureless in that there were no associated migrainous or cranial autonomic features. The exacerbation was severe, bilateral and throbbing. It was associated with nausea, vomiting, photophobia, phonophobia, worsening with movement and nasal blockage. She had a visual aura in the form of flashing lights in the whole of the visual field a few minutes prior to the

headache. The visual aura lasted 15–30 min. The typical exacerbation lasted from 6 h to up to 2 days. Alcohol, hunger, over exertion, menstruation and weather change could trigger the exacerbation.

In early 2002 she had bilateral GON injections on three occasions, with which there was benefit to the headache for 4–5 days after the procedure. Her mother suffers from migraine. Neurological examination was unremarkable.

In May 2002, bilateral suboccipital stimulators were sited. The stimulators have been highly effective, rendering the patient pain free within 25 min.

Case 7

A 44-year-old, right-handed female presented in early 2001 with a 5-year history of daily headaches. She had had migraine with aura since the age of 11 years. In 1987 the frequency and duration of the headaches began to increase gradually, such that since August 1996 she has had daily headaches. On 10–15 days per month she had a background headache, which was holocranial, moderately severe and tightening or pressing in quality; she denied any migrainous or cranial autonomic features in association with the background headache. On the remaining 15–20 days per month she had a severe exacerbation of the headache. The usual exacerbation lasted 2–4 days and occurred four or five times per month. The exacerbations were bilateral, started over the occiput before becoming holocranial, and had a throbbing quality. They were associated with nausea, vomiting, photophobia and phonophobia, and worsened with movement. She also reported bilateral ptosis, eyelid oedema, lacrimation, nasal blockage and rhinorrhoea in association with the exacerbations. She reported visual aura symptoms in the form of flashing lights in the whole visual field; these occurred ~30 min prior to the onset of the some exacerbations and lasted 5–10 min. Alcohol, menstruation, over exertion and over sleeping could trigger an exacerbation. In the family history, her father and brother suffer from migraine. General and neurological examinations were normal.

In May 2001 bilateral GON injections were performed; she developed an area of numbness over the GON distributions and there was a marked reduction of pain which lasted ~24 h. Subsequently, she had two further trials of GON injections, with which there was no benefit to the headache. In August 2001, bilateral suboccipital stimulators were sited. They were highly effective, markedly reducing the severity of pain from severe [verbal rating scale (VRS) 8–9/10] to mild (VRS 1–3/10) over 15 min.

Case 8

A 42-year-old, right-handed female presented in 1999 with a history of daily headaches since 1993. Her headaches started about a week after she fell and banged her head. For the first 3–6 months the headaches were episodic; thereafter, she has had daily headache. The background headache was holocranial, mild to moderate in severity, had a tightening quality and was completely featureless. The exacerbation was bilateral, centred on the occiput and showed holocranial radiation. It was associated with nausea, vomiting, photophobia, phonophobia, worsening with movement, conjunctival injection, lacrimation and rhinorrhoea. She denied osmophobia, any symptoms suggestive of a migrainous aura or any other cranial autonomic features. The exacerbation could be triggered by change of weather, menstruation, alcohol, over sleeping and over exertion.

In the family history her mother has migraine. Neurological examination was unremarkable.

She had bilateral GON injections in 1999, with which there was a marked reduction in the headache that was sustained for 6–8 weeks. In December 1999 bilateral suboccipital stimulators were sited, with which there has been a marked improvement. On switching the stimulator on there is immediate benefit and the headache is suppressed within 15 min.

PET study design

Each patient had 12 consecutive radioactive $H_2^{15}O$ PET scans in the following three states: (1) stimulator at optimum settings: patient pain-free and with paraesthesia; (2) stimulator off: patient in pain and no paraesthesia; (3) stimulator partially activated: patient with intermediate levels of pain and paraesthesia. Four scans were performed in each state. The order of the states in which the patients were scanned was randomized and counterbalanced across subjects. At the end of each scan, patients rated their headache intensity on a VRS (0 = no pain, 10 = the most severe pain) and scored their paraesthesia (0 = no paraesthesia, 5 = strongest paraesthesia). On the day prior to scanning, the patients underwent a trial in which the time course of the stimulator effect was assessed and the patients were trained to rate their pain sensation and paraesthesia. Throughout the scan, the patients experienced no pain or sensory symptoms apart from those related to the headache and the suboccipital stimulators. Participants had their eyes closed during all scans.

Data acquisition

The PET scans were obtained with an ECAT EXACT HR+ scanning system (CTI, Knoxville, TN, USA) in 3D mode with collimating septa retracted. An antecubital vein cannula was used to administer the tracer. For each measurement of relative rCBF, 9 mCi of $H_2^{15}O$ was given as an intravenous bolus over 20 s, followed by a 20 s saline flush. Integrated radioactivity counts were accumulated over a 90 s acquisition period, beginning 5 s before the peak of radioactivity registered in the head. The interval between scans was 8–30 min, allowing adequate decay of radioactivity and acquisition of the conditions of interest. A transmission scan was obtained prior to collection of the emission data to correct for radiation attenuation by tissues in the head. The corrected data were reconstructed into 63 transverse planes (separation 2.4 mm) and into a 128×128 pixel image matrix (pixel size 2.1×2.1 mm²) by 3D filtered back-projection.

Statistical analysis

The data were analysed with Statistical Parametric Mapping (SPM) 99 (Wellcome Department of Imaging Neuroscience, London, UK, <http://www.fil.ion.ucl.ac.uk/spm>) implemented in MATLAB (Mathworks, USA) and run on a SPARC workstation (Sun Microsystems). The images were initially realigned with reference to the first image to correct for motion artefact and then spatially normalized into a standard stereotactic space defined by the atlas of Talairach and Tournoux (Talairach and Tournoux, 1988). The normalized images were smoothed with a 10 mm isotropic full-width half-maximum Gaussian kernel to account for intersubject differences in anatomy and to allow valid statistical inference according to Gaussian random field theory.

Statistical analysis was performed using a multisubject, single-group fixed-effects model, in which the pain scores and paraesthesia scores (as a marker of stimulation) were modelled as separate covariates across the group. In addition, the effect of global differences in cerebral blood flow between scans was modelled as a covariate of no interest by subject-specific analysis of covariance scaling of activity to a nominal mean global activity of 50 ml/100 g/min. The resulting covariates were used in a general linear model. The parameter estimates for each covariate resulting from the least mean squares fit of the model to the data were calculated and SPM{*F*} resulting from linear contrasts of covariates were generated and stored as separate images (thresholded at $P < 0.001$, uncorrected for multiple comparisons). *F*-tests were used because we had no *a priori* hypothesis about the nature of the relationship between covariate and rCBF for a number of regions. Small volume corrections (sphere of radius 10 mm) were applied across the regions of interest defined in the *a priori* hypothesis. The coordinates for the regions of interest were predefined on the basis of experimental data in the literature (Weiller *et al.*, 1995; Hautvast *et al.*, 1997; Baha *et al.*, 2001) (Table 1). Significant voxels are reported at $P < 0.05$, corrected for multiple comparisons. A separate model in which each of the states (1), (2) and (3) were employed as covariates was used to identify the parameter estimates (or average relative changes in rCBF) in each condition across the group, in order to better describe the data (Fig. 6) at voxels of interest.

The association between the pain score ratings and stimulator-induced paraesthesia was determined using Pearson's correlation coefficient and standard linear regression.

Results

Suboccipital stimulators in chronic migraine patients

Eight patients underwent 12 implant procedures for the treatment of chronic migraine. The only immediate post-operative complication reported was the development of an abdominal haematoma at the implantation site of the receiver/generator. Three patients have needed revisions after the initial implantation because of lead migration; one of these patients has needed two revisions. All patients reported that switching on the stimulator rapidly suppressed the pain but it recurred instantaneously when the stimulator was switched off.

Four patients have had an excellent response; their headaches are completely suppressed and they rarely have breakthrough headaches. Two patients described their response to stimulation as very good; the headaches are completely suppressed most of the time, though they have breakthrough headaches on about 10 days per month, for which they either have to take analgesics or increase the stimulation amplitude. The other two patients continued to have constant headaches but both reported their response to stimulation as good, with the severity of the headaches reduced by 50–75%; one of these patients had derived further benefit from implanted bilateral supraorbital stimulators. All patients reported that they had managed to either completely stop or considerably reduce the headache medications they were taking.

Table 1 Talairach coordinates of regions of interest defined in the *a priori* hypothesis

Region of interest	Talairach coordinates (mm)		
	<i>x</i>	<i>y</i>	<i>z</i>
Pain			
Pons	–2	–28	–22
ACC	0	30	18
Right insula	28	–26	0
Left insula	–34	–30	0
Right thalamus	12	–4	10
Left thalamus	–12	–4	10
Paraesthesia			
PAG	4	–26	–16
ACC	0	30	18
Right insula	28	–26	0
Left insula	–34	–30	0
Right pulvinar	16	–32	8
Left pulvinar	–16	–32	8

The eight patients have now been followed up for a period ranging from 7 months to 3 years, averaging over 1.5 years. In all patients the initial beneficial response has been maintained throughout the follow-up period.

Psychophysical data

Figure 1 shows the results of the pain assessment session on the day prior to scanning. On switching off the stimulator, the headache recurred immediately and peaked within 20 min. On switching on the stimulator, the headache began to improve immediately and within 30 min rendered six patients pain-free while the other two had only mild residual pain. All patients reported that the effect of suboccipital stimulation on the time course of pain recurrence and relief was highly consistent.

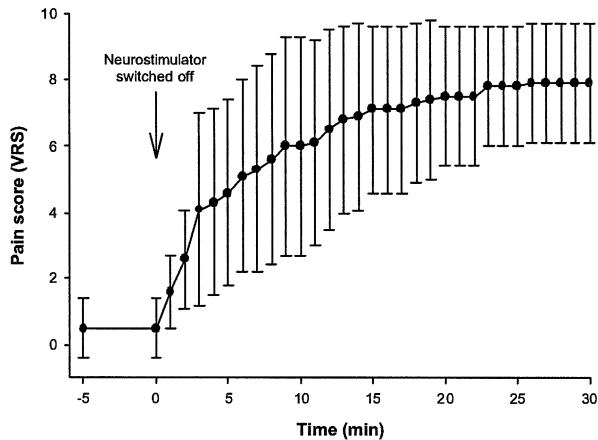
Pain and paraesthesia scores obtained during the PET scans were negatively correlated. Pearson's correlation coefficient was -0.61 ($P < 0.001$). Figure 2 shows the scatter plot of pain and paraesthesia scores, and the plot of standard linear regression. Figure 3 shows the mean pain and paraesthesia score by the scanning state.

PET data

Pain analysis

The regions in which rCBF covaried with pain scores were the dorsal rostral pons, right lentiform nucleus, head of the right caudate nucleus, ACC, postcentral gyrus [Brodmann area (BA) 1/2/3], left frontal cortex (BA 11), right frontal cortex (BA 44), right temporal cortex (BA 22), cuneus, precuneus, right occipital cortex (BA 18), left occipital cortex (BA 19) and cerebellum ($P < 0.001$ uncorrected for multiple comparisons). The coordinates and the *Z* scores of these regions are listed in Table 2.

(A) Sub-occipital stimulator switched off



(B) Suboccipital stimulator switched on

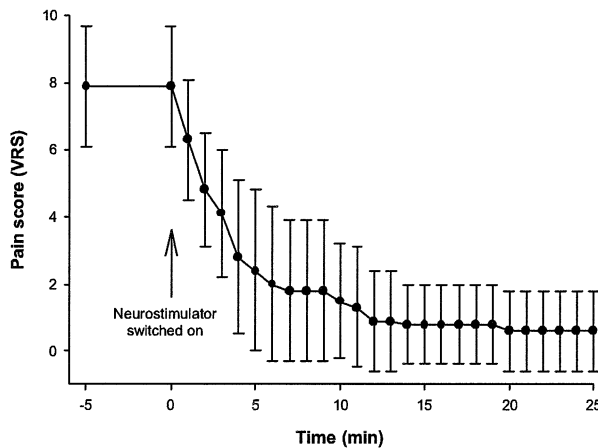


Fig. 1 Time course of the pain scores reported by chronic migraine patients ($n = 8$) when the suboccipital stimulator is (A) switched off and (B) switched on. The pain intensity is expressed on the VRS (0 = no pain; 10 = most severe pain).

Small volume corrections applied to the regions identified according to our prior hypothesis showed significant voxels ($P < 0.05$, corrected for multiple comparisons) at the dorsal rostral pons ($x = 0$, $y = -26$, $z = -24$, Z score = 3.65) and the ACC ($x = -2$, $y = 24$, $z = 18$, Z score = 4.09). In the dorsal rostral pons, activity was increased in states 1 and 2 relative to state 3; there was no significant difference in activity between states 1 and 2. Activity in the ACC was decreased in state 1 and increased in state 2 relative to state 3 (Figs 4 and 6).

The volume summary generated by SPM99 for an analysis lists both the whole-volume corrected and uncorrected significance level at each voxel. An inspection of the whole-volume corrected significance levels revealed that the activation at the cuneus ($x = 2$, $y = -84$, $z = 34$, Z score =

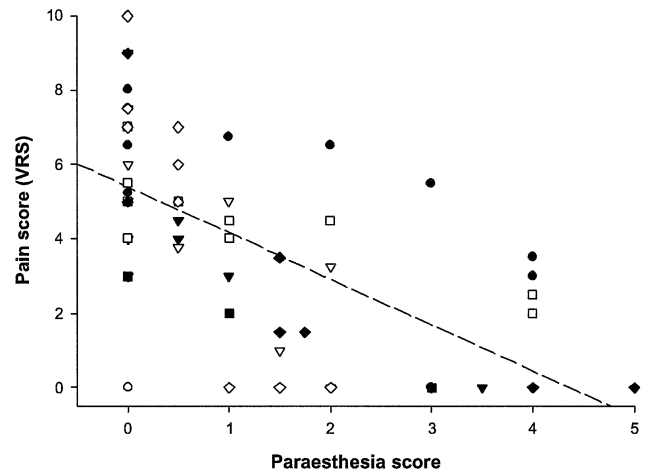


Fig. 2 Graph of pain scores (VRS: 0 = no pain; 10 = most severe pain) versus stimulator-induced paraesthesia (0 = no paraesthesia, 5 = strongest paraesthesia) in chronic migraine patients ($n = 8$). Each symbol represents the results from an individual patient. Dashed line is the plot of standard linear regression (intercept = 5.4 ± 0.3 ; regression coefficient = -1.2 ± 0.2 ; $P < 0.05$; $r^2 = 0.38$).

4.90) was significant ($P = 0.026$). Parameter estimates revealed that activity in the cuneus was decreased in state 2 and increased in state 3 relative to state 1 (Figs 4 and 5).

Paraesthesia analysis

The regions in which rCBF covaried with paraesthesia scores were the dorsal rostral pons, left pulvinar, bilateral insulae, ACC, left frontal cortex (BA 11), right frontal cortex (BA 11), left temporal cortex (BA 11, 21, 41), right temporal cortex (BA 20/37), parahippocampal gyrus (BA 35), cuneus, precuneus and right occipital cortex (BA 19) ($P < 0.001$ uncorrected for multiple comparisons). The coordinates and the Z scores of these regions are listed in Table 3.

Small volume corrections applied to the regions identified according to our prior hypothesis showed significant voxels ($P < 0.05$, corrected for multiple comparisons) at the left pulvinar ($x = -16$, $y = -32$, $z = 10$) and the ACC ($x = -2$, $y = 24$, $z = 18$, Z score = 4.23, Z score = 3.49). Activity in the left pulvinar was increased in state 1 and decreased in state 2 relative to state 3. The ACC coordinates are the same as those obtained in the pain analysis and, hence, the activation pattern is the same (Figs 5 and 6).

Discussion

Suboccipital stimulation in chronic migraine

We have described eight cases of chronic migraine who have responded very well to implanted bilateral suboccipital stimulation. All patients report that stimulation rapidly suppresses the pain and that it recurs instantaneously when stimulation is ceased, necessitating continuous use of the

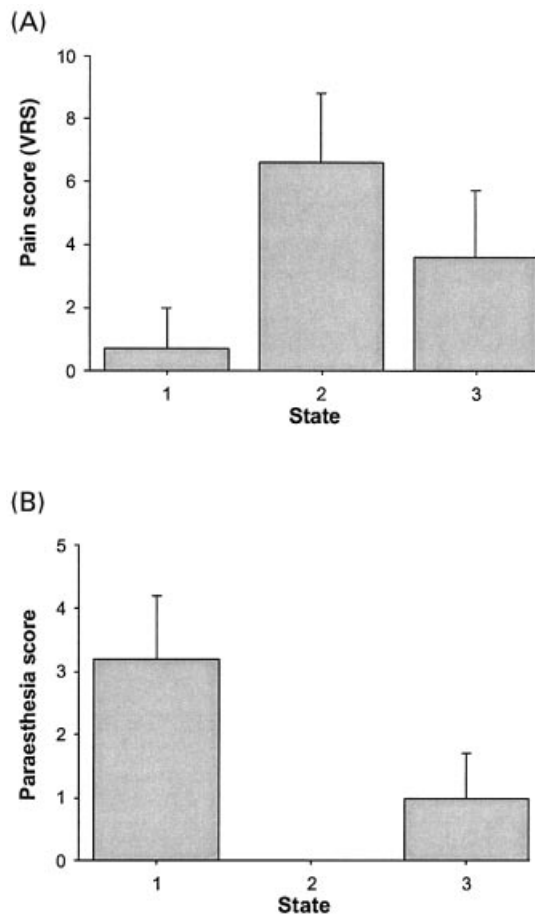


Fig. 3 Graphs showing (A) mean pain scores and (B) mean scores of stimulator-induced paraesthesia by scanning states. The scanning states were: (1) stimulator at optimum settings: patient pain-free or with mild pain and paraesthesia; (2) stimulator off: patient in pain and no paraesthesia; (3) stimulator partially activated; patient with intermediate levels of pain and paraesthesia.

device. The patients have been able to either completely discontinue or markedly reduce the intake of abortive and preventative medications for headaches. This group of patients have displayed sustained efficacy with this treatment over an average follow-up period of 1.5 years. Besides electrode migration, which occurred in three patients and required re-implantation, and the development of a minor, self-limiting abdominal haematoma in one patient, there have been no other complications. Hence, implanted suboccipital stimulation is a new and effective therapeutic option in the management of medically intractable chronic migraine.

The ultimate confirmation of the utility of a new therapeutic modality should come from randomized, double-blind, placebo-controlled trials. In various pain conditions, the placebo effect explains up to 35% of the pain reduction during treatment (Hrobjartsson and Gotzsche, 2001). This poses a special problem in designing blinded studies of treatment with stimulation since there is no placebo

Table 2 Talairach coordinates and Z scores of areas with rCBF changes covariate with pain scores

Region	Coordinates			Z score ($P < 0.001$)
	x	y	z	
Dorsal rostral pons ^a	0	-26	-24	3.65
Lentiform nucleus	22	6	-2	3.70
Caudate nucleus (head of)	12	-2	16	3.57
ACC (BA 24 ^a)	-2	24	18	4.09
Left frontal cortex (BA11)	-24	32	-18	3.82
Right frontal cortex (BA44)	40	18	12	4.12
Postcentral gyrus (BA 1/2/3)	-36	-22	52	4.18
Right temporal cortex (BA 22)	58	-44	20	3.81
Cuneus ^b	2	-84	34	4.90
Precuneus	8	-46	62	4.17
Right occipital cortex (BA 18)	18	-92	0	4.11
Left occipital cortex BA19	-8	-66	4	3.85
Cerebellum	0	-58	-16	4.03
Right cerebellum	28	-48	-48	3.70
Right cerebellum	34	-76	-28	3.69
Left cerebellum	-52	-60	-30	3.55

Z score $P < 0.001$ uncorrected for multiple comparisons. Each location is a peak within a cluster (defined as the voxel with the highest Z score). ^aRegions significant after small volume corrections ($P < 0.05$, corrected for multiple comparisons). ^bRegion significant with whole volume correction ($P < 0.05$).

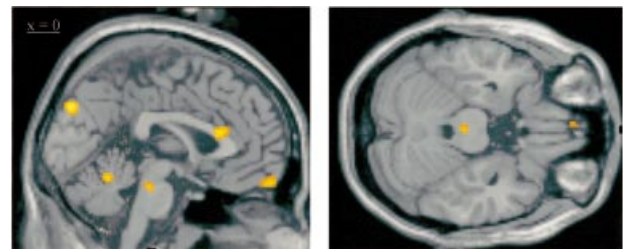


Fig. 4 Statistical parametric map (SPM{F}) showing brain regions in which rCBF correlates (positively or negatively) with pain scores, in particular the dorsal rostral pons, ACC and cuneus (voxels significant at $P < 0.001$, uncorrected for display purposes).

equivalent for the paraesthesia that accompanies stimulation. Any credible sham device would, therefore, be required to produce a discernible stimulus, which could then be criticized for providing neurostimulation. The results reported here are very encouraging, given the very clearly intractable nature of these cases.

PET study

Methodological considerations

Ideally, the design of the study would have included a fourth state, namely stimulation off and the patient pain-free. This would have allowed us to determine the effects of pain, by a contrast with state 1 (stimulation off and the patient in pain), and the effects of paraesthesia, by a contrast with state 2

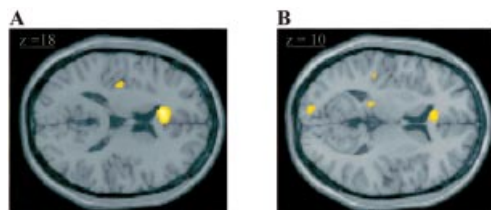


Fig. 5 SPM{*F*} showing brain regions in which rCBF correlates (positively or negatively) with paraesthesia scores. (A) ACC. (B) Pulvinar nucleus of the thalamus. Voxels significant at $P < 0.001$, uncorrected for display purposes.

(stimulation on and the patient pain-free). This would have been possible if the patients had remained pain-free for a period of time after stimulation was switched off. Unfortunately, in our patient group the pain recurred immediately and was already at a moderate intensity within 5 min, thus making it impossible to obtain scans in this state. Consequently, we used a parametric approach in an attempt to delineate the brain regions involved in pain and with stimulation-induced paraesthesia. As pain and paraesthesia scores in our patients were fairly well correlated, we expected the covariate analysis of pain and paraesthesia to show common foci of activation. This was borne out in the results of the analysis with a threshold of $P < 0.001$ uncorrected. Changes in rCBF covarying with both pain and paraesthesiae were observed in the dorsal rostral pons, ACC, left frontal cortex, cuneus, precuneus and cerebellum (Tables 2 and 3). However, the key issue in the interpretation of the data is the direction of change in rCBF, since pain and paraesthesia scores are negatively correlated. This was ascertained by determining the parameter estimates at the peak voxel of the significant regions across the three states.

An inherent problem with PET studies of neurostimulation is the timing of the conditions. Poststimulation analgesia has been described in humans (Wall and Sweet, 1967) and has been attributed to activation of central structures beyond the stimulation period (Roberts and Rees, 1986; Linderoth and Meyerson, 2002). One approach is to acquire pain scans at the beginning of the experimental session and the pain-free scans subsequently (Hautvast *et al.*, 1997; Kupers *et al.*, 2000). However, it could then be argued that the observed rCBF changes between the pain and pain-free states might reflect monotonic state-independent time effects rather than pain or paraesthesia-related changes. In our group of patients, we did not observe poststimulation analgesia, and therefore it is likely that central structures are not modulated by stimulation beyond the stimulation period. For this reason we chose to randomize the order of the states.

Pain and paraesthesia-related rCBF changes

We observed significant changes in rCBF correlated to the pain of chronic migraine at the dorsal rostral pons, ACC and cuneus and correlated to stimulation-induced paraesthesia at

Table 3 Table showing the Talairach coordinates and Z scores of areas with rCBF changes covariate with paraesthesia scores

Region	Coordinates			Z score ($P < 0.001$)
	x	y	z	
Dorsal rostral pons	-2	-26	-24	3.41
Pulvinar*	-16	-32	10	3.49
Right insula	38	4	-10	3.58
Left insula	-36	-16	16	3.54
ACC ^a	-2	24	18	4.23
Right frontal cortex (BA 11)	18	34	-18	3.81
Left frontal cortex (BA 11)	-22	32	-22	3.50
Left temporal cortex (BA 21)	-52	-46	2	3.99
Left temporal cortex (BA 41)	-46	-28	6	3.90
Right temporal cortex (BA 20/37)	58	-34	-26	3.80
Parahippocampal gyrus (BA 35)	-12	4	-34	4.37
Cuneus	0	-84	36	4.07
Precuneus	8	-46	64	3.44
Right occipital cortex (BA 19)	52	-62	-10	3.50
Cerebellum	2	-58	-18	3.79
Left cerebellum	-52	-60	-26	4.51
Left cerebellum	-28	-86	-28	4.16
Right cerebellum	30	-44	-28	3.67

Z scores $P < 0.001$ uncorrected for multiple comparisons. Each location is a peak within a cluster (defined as the voxel with the highest Z score). ^aRegions significant after small volume corrections ($P < 0.05$, corrected for multiple comparisons).

the ACC and left pulvinar. The relative activation of the ACC is directly correlated to pain scores and inversely correlated to paraesthesia scores. The relative activation of the left pulvinar and the cuneus is directly correlated to paraesthesia scores and inversely correlated to pain scores. The relative activity of the dorsal rostral pons was increased in states 1 and 2 relative to state 3; there was no significant difference in the activity between states 1 and 2. This activation pattern of the dorsal rostral pons does not simply mirror either pain or paraesthesia scores. So what is the explanation for this activation pattern in the dorsal rostral pons?

Brainstem and migraine

It has been postulated that the brainstem plays a pivotal role in migraine (Goadsby *et al.*, 1982, 1991; Welch *et al.*, 2001). The first evidence in humans to indicate a potential role for PAG dysfunction in migraine came from observations that non-migraine patients with PAG electrode implantation for chronic pain sometimes developed migraine-like headache (Raskin *et al.*, 1987). These observations were subsequently confirmed in a larger number of patients (Veloso *et al.*, 1998). A multiple sclerosis plaque in the PAG (Haas *et al.*, 1993), a midbrain arteriovenous malformation (Goadsby, 2002) and a brainstem cavernoma (Afridi and Goadsby, 2003) have been reported to produce migraine-like headaches. Using functional imaging methods, activation in brainstem regions, notably the PAG (Weiller *et al.*, 1995) and dorsolateral pons (Bahra *et al.*, 2001), has been reported. This activation pattern

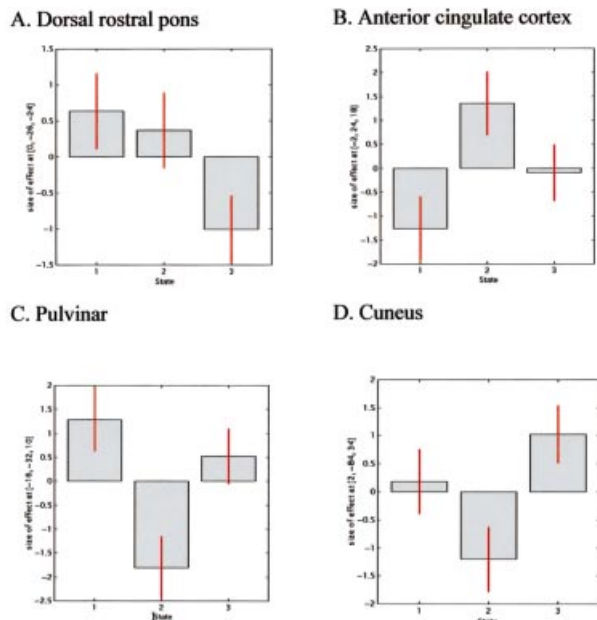


Fig. 6 Parameter estimates (or average relative changes in rCBF) plotted against scanning conditions for the regions of interest: (A) dorsal rostral pons ($x = 0$, $y = -26$, $z = -24$); (B) anterior cingulate cortex ($x = -2$, $y = 24$, $z = 18$); (C) pulvinar ($x = -16$, $y = -32$, $z = 10$); (D) cuneus ($x = 2$, $y = -84$, $z = 34$). The scanning states were: (1) stimulator at optimum settings: patient pain-free or with mild pain and paraesthesia; (2) stimulator off: patient in pain and no paraesthesia; (3) stimulator partially activated; patient with intermediate levels of pain and paraesthesia.

seems specific for migraine, given that these areas have not been observed in acute cluster headache (May *et al.*, 1998a, 2000), SUNCT (short-lasting unilateral neuralgiform headache attacks with conjunctival injection and tearing) syndrome (May *et al.*, 1999), atypical facial pain (Derbyshire *et al.*, 1994) and experimentally induced facial pain (May *et al.*, 1998b).

A plausible explanation for the changes in the dorsal rostral pons is that they reflect a constant dysfunctional activation of this structure, as might be predicted in chronic migraine. This would be consistent with the almost immediate re-emergence of the pain when the stimulator is turned off, and is exactly what would be predicted from the ongoing activation in the brainstem seen after successful treatment of pain in both reported episodic migraine studies (Weiller *et al.*, 1995; Bahra *et al.*, 2001). This analysis suggests that the effect of suboccipital stimulation may be at a site other than the dorsal rostral pons. This is consistent with our observation of a patient with hemicrania continua responding to suboccipital stimulation (unpublished case, M. S. Matharu, T. Bartsch, R. Weiner and P. J. Goadsby) and preliminary reports of patients with chronic cluster headache responding (Dodick, Late-Breaking Abstract, 14th Migraine Trust International Symposium, London, September 2002; unpublished observations, P. J. Goadsby and Watkins).

Pulvinar

Some PET studies of chronic pain have demonstrated pulvinar activation with pain relief. Hsieh and colleagues studied a group of neuropathic pain patients, observing an increase in rCBF in the pulvinar nucleus on alleviation of the pain by anesthetic blocks (Hsieh *et al.*, 1995). A patient with a thalamic stimulator for chronic facial pain was reported to have a relative increase in rCBF in the bilateral pulvinar nuclei when the pain was abolished by stimulation (Kupers *et al.*, 2000). Left pulvinar activation with spinal cord stimulation in patients with refractory angina pectoris has been noted (Hautvast *et al.*, 1997), although this effect is secondary to stimulation rather than pain alleviation since the patients were pain-free throughout the study. In keeping with these reports, we observed an increase in rCBF in the left pulvinar nucleus on alleviation of pain of chronic migraine by suboccipital stimulation.

In cats, pulvinar neurons respond to noxious and non-noxious peripheral stimuli, but only after relatively long delays of up to several hundred milliseconds (Kudo *et al.*, 1968). In the primate, the pulvinar has been shown to receive nociceptive input and to project to the sensory cortex and posterior parietal cortex (Yeterian and Pandya, 1985; Friedman and Murray, 1986; Gingold *et al.*, 1991). The pulvinar has been suggested to provide the information necessary for the synthesis of somatosensory input and to participate in affective association (Yeterian and Pandya, 1988; Schmahmann and Pandya, 1990). Furthermore, pulvinothomy and electrical stimulation of the pulvinar have been used successfully in the treatment of chronic pain in humans (Gybels and Sweet, 1989). With the available information, it is difficult to determine whether the activation of the pulvinar mediates pain relief or is just associated with it.

Cuneus

An unexpected finding was changes in rCBF in the cuneus that were directly correlated to paraesthesia scores and inversely correlated to pain scores. A functional MRI study investigating the affective dimension of pain reported right cuneus activation, which the authors attributed to the anticipation and subjective experience of pain (Fulbright *et al.*, 2001). Perhaps there is a similar anticipatory role here.

Conclusions

We have reported eight patients with chronic migraine who have shown a marked response with implantation of bilateral suboccipital stimulators. The beneficial response has been maintained for an average follow-up period of 1.5 years. A PET study in this group of chronic migraineurs with implanted suboccipital stimulators showed significant changes in rCBF in the dorsal rostral pons, ACC and cuneus correlated to pain scores and in the ACC and left pulvinar correlated to stimulation-induced paraesthesia scores.

Suboccipital stimulation-modulated activity in the left pulvinar, ACC and cuneus is probably involved in the affective dimension of pain. The activation pattern at the dorsal rostral pons is highly suggestive of a role for this structure in the pathophysiology of chronic migraine and supports the view that episodic and chronic migraine are on the same neurobiological spectrum, representing disorders of the brain.

Acknowledgements

M.S.M. is a Migraine Trust Research Fellow, T.B. is supported by a grant from Deutsche Forschungsgemeinschaft and N.W., R.S.J.F. and P.J.G. are supported by the Wellcome Trust. This work was presented in preliminary form at the 55th Meeting of the American Academy of Neurology, Honolulu, Hawaii, 2 April 2003 (Matharu *et al.*, 2003).

References

- Afridi S, Goadsby PJ. New onset migraine with a brain stem cavernous angioma. *J Neurol Neurosurg Psychiatry* 2003; 74: 680–2.
- Bahra A, Matharu MS, Buchel C, Frackowiak RSJ, Goadsby PJ. Brainstem activation specific to migraine headache. *Lancet* 2001; 357: 1016–7.
- Castillo J, Muñoz P, Guitera V, Pascual J. Epidemiology of chronic daily headache in the general population. *Headache* 1999; 39: 190–6.
- Derbyshire SW, Jones AK, Devani P, Friston KJ, Feinmann C, Harris M, et al. Cerebral responses to pain in patients with atypical facial pain measured by positron emission tomography. *J Neurol Neurosurg Psychiatry* 1994; 57: 1166–72.
- Frackowiak RSJ, Friston KJ. Functional neuroanatomy of the human brain: positron emission tomography—a new neuroanatomical technique. *J Anat* 1994; 184: 211–25.
- Friedman DP, Murray EA. Thalamic connectivity of the second somatosensory area and neighboring somatosensory fields of the lateral sulcus of the macaque. *J Comp Neurol* 1986; 252: 348–73.
- Fulbright RK, Troche CJ, Skudlarski P, Gore JC, Wexler BE. Functional MR imaging of regional brain activation associated with the affective experience of pain. *AJR Am J Roentgenol* 2001; 177: 1205–10.
- Gingold SI, Greenspan JD, Apkarian AV. Anatomic evidence of nociceptive inputs to primary somatosensory cortex: relationship between spinothalamic terminals and thalamocortical cells in squirrel monkeys. *J Comp Neurol* 1991; 308: 467–90.
- Goadsby PJ. Neurovascular headache and a midbrain vascular malformation—evidence for a role of the brainstem in chronic migraine. *Cephalalgia* 2002; 22: 107–11.
- Goadsby PJ, Lambert GA, Lance JW. Differential effects on the internal and external carotid circulation of the monkey evoked by locus coeruleus stimulation. *Brain Res* 1982; 249: 247–54.
- Goadsby PJ, Zagami AS, Lambert GA. Neural processing of craniovascular pain: a synthesis of the central structures involved in migraine. *Headache* 1991; 31: 365–71.
- Goadsby PJ, Lipton RB, Ferrari MD. Migraine—current understanding and treatment. *New Engl J Med* 2002; 346: 257–70.
- Gybels JM, Sweet WH. Neurosurgical treatment of persistent pain. Physiological and pathological mechanisms of human pain. *Pain Headache* 1989; 11: 1–402.
- Haas DC, Kent PF, Friedman DI. Headache caused by a single lesion of multiple sclerosis in the periaqueductal gray area. *Headache* 1993; 33: 452–5.
- Hautvast RW, Ter Horst GJ, DeJong BM, DeJongste MJ, Blanksma PK, Paans AM. Relative changes in regional cerebral blood flow during spinal cord stimulation in patients with refractory angina pectoris. *Eur J Neurosci* 1997; 9: 1178–83.
- Headache Classification Committee of The International Headache Society. The International Classification of Headache Disorders. 2nd ed. *Cephalalgia* 2004; 24: 1–160.
- Hrobjartsson A, Gotzsche PC. Is the placebo powerless? An analysis of clinical trials comparing placebo with no treatment. *New Engl J Med* 2001; 344: 1594–602.
- Hsieh JC, Belfrage M, Stone-Elander S, Hansson P, Ingvar M. Central representation of chronic ongoing neuropathic pain studied by positron emission tomography. *Pain* 1995; 63: 225–36.
- Kudo T, Yoshii N, Shimizu S, Aikawa S, Nishioka S, Nakahama H. Stereotaxic thalamotomy for pain relief. [Japanese]. *Seishin Igaku Kenkyusho Gyosekishu* 1968; 15: 15–30.
- Kupers RC, Gybels JM, Gjedde A. Positron emission tomography study of a chronic pain patient successfully treated with somatosensory thalamic stimulation. *Pain* 2000; 87: 295–302.
- Lanteri-Minet M, Auray JP, El Hasnaoui A, Dartigues JF, Duru G, Henry P, et al. Prevalence and description of chronic daily headache in the general population in France. *Pain* 2003; 102: 143–9.
- Linderoth B, Meyerson BA. Spinal cord stimulation: mechanism of action. In: Burchiel K, editor. *Surgical management of pain*. New York: Thieme; 2002. p. 505–26.
- Matharu MS, Bartsch T, Ward N, Frackowiak RSJ, Weiner RL, Goadsby PJ. Central neuromodulation in chronic migraine with implanted suboccipital stimulators [abstract]. *Neurology* 2003; 60 (5 Suppl): A404–5.
- May A, Bahra A, Buchel C, Frackowiak RSJ, Goadsby PJ. Hypothalamic activation in cluster headache attacks. *Lancet* 1998a; 352: 275–8.
- May A, Kaube H, Buchel C, Eichten C, Rijntjes M, Juptner M, et al. Experimental cranial pain elicited by capsaicin: a PET-study. *Pain* 1998b; 74: 61–6.
- May A, Bahra A, Buchel C, Turner R, Goadsby PJ. Functional magnetic resonance imaging in spontaneous attacks of SUNCT: short-lasting neuralgiform headache with conjunctival injection and tearing. *Ann Neurol* 1999; 46: 791–4.
- May A, Bahra A, Buchel C, Frackowiak RSJ, Goadsby PJ. PET and MRA findings in cluster headache and MRA in experimental pain. *Neurology* 2000; 55: 1328–35.
- Raskin NH, Hosobuchi Y, Lamb S. Headache may arise from perturbation of brain. *Headache* 1987; 27: 416–20.
- Roberts MH, Rees H. The antinociceptive effects of stimulating the pretectal nucleus of the rat. *Pain* 1986; 25: 83–93.
- Scher A, Stewart WF, Liberman J, Lipton RB. Prevalence of frequent headache in a population sample. *Headache* 1998; 38: 497–506.
- Schmahmann JD, Pandya DN. Anatomical investigation of projections from thalamus to posterior parietal cortex in the rhesus monkey: a WGA-HRP and fluorescent tracer study. *J Comp Neurol* 1990; 295: 299–326.
- Silberstein SD, Lipton RB. Chronic daily headache. In: Silberstein SD, Lipton RB, Dalessio DJ, editors. *Wolff's headache and other head pain*. 7th ed. New York: Oxford University Press; 2001. p. 247–82.
- Silberstein SD, Lipton RB, Sliwinski M. Classification of daily and near-daily headaches: a field study of revised IHS criteria. *Neurology* 1996; 47: 871–5.
- Talairach J, Tournoux P. *Coplanar stereotaxic atlas of the human brain*. Stuttgart: Thieme, 1988.
- Veloso F, Kumar K, Toth C. Headache secondary to deep brain implantation. *Headache* 1998; 38: 507–15.
- Wall PD, Sweet WH. Temporary abolition of pain in man. *Science* 1967; 155: 108–9.
- Wang S-J, Fuh J-L, Lu S-R, Liu C-Y, Hsu L-C, Wang P-N, et al. Chronic daily headache in Chinese elderly. Prevalence, risk factors, and biannual follow-up. *Neurology* 2000; 54: 314–9.
- Weiller C, May A, Limmroth V, Juptner M, Kaube H, Schayck RV, et al. Brain stem activation in spontaneous human migraine attacks. *Nat Med* 1995; 1: 658–60.
- Weiner R. Peripheral nerve stimulation. In: Burchiel K, editor. *Surgical management of pain*. New York: Thieme; 2002. p. 496–504.

- Weiner RL, Reed KL. Peripheral neurostimulation for control of intractable occipital neuralgia. *Neuromodulation* 1999; 2: 217–21.
- Welch KMA, Goadsby PJ. Chronic daily headache: nosology and pathophysiology. *Curr Opin Neurol* 2002; 15: 287–95.
- Welch KM, Nagesh V, Aurora S, Gelman N. Periaqueductal grey matter dysfunction in migraine: cause or the burden of illness? *Headache* 2001; 41: 629–37.

- Yeterian EH, Pandya DN. Corticothalamic connections of the posterior parietal cortex in the rhesus monkey. *J Comp Neurol* 1985; 237: 408–26.
- Yeterian EH, Pandya DN. Corticothalamic connections of paralimbic regions in the rhesus monkey. *J Comp Neurol* 1988; 269: 130–46.

*Received April 15, 2003. Revised August 24, 2003.
Accepted August 25, 2003*